

Claudio Stacchi, Giuseppe Troiano, Federico Berton, Teresa Lombardi, Antonio Rapani, Andrea Englaro, Fabio Galli, Tiziano Testori, Myron Nevins

Piezoelectric bone surgery for lateral sinus floor elevation compared with conventional rotary instruments: A systematic review, meta-analysis and trial sequential analysis

KEY WORDS

intraoperative complications, membrane perforation, piezosurgery, sinus floor elevation

ABSTRACT

Aims: To evaluate whether piezoelectric bone surgery (PBS) for lateral maxillary sinus floor elevation reduces risk of intraoperative complications, requires prolonged surgical time and improves the survival rate of dental implants in comparison with conventional rotary instruments.

Materials and methods: This meta-analysis followed PRISMA guidelines and was registered in the PROSPERO database (CRD42019122972). The PubMed, Embase, Scopus and Open Grey databases were screened for articles published from 1 January 1990 to 31 December 2018. The selection criteria included randomised controlled trials (RCTs) and case-control studies (CCTs) comparing PBS with rotary instruments in lateral sinus augmentation and reporting intraoperative and postoperative outcomes (e.g. sinus membrane perforations, surgical time and implant failure rate). The risk of bias assessment was performed using the Cochrane Collaboration's tool for RCTs. A meta-analysis was performed, and the power of the meta-analytic findings was assessed via trial sequential analysis (TSA).

Results: Four RCTs met the inclusion criteria and were included in the review. The meta-analysis showed that, although a lower incidence of membrane tearing occurred when using PBS, the difference between the two groups was not significant. However, the power of evidence for this outcome, as determined by the TSA, was weak. Moreover, there was moderate evidence suggesting that PBS prolongs the surgery duration (mean difference of 3.43 minutes), whilst insufficient data was present to assess if PBS improves the survival rate of implants inserted in augmented sinuses.

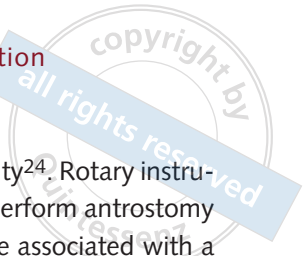
Conclusions: The power of the evidence was too weak to confirm the above-mentioned findings and further well-designed randomised clinical trials are needed to draw definitive conclusions.

Conflict-of-interest statement: *The authors report no conflicts of interest related to this study. This study received no external funding.*

Introduction

Alveolar remodelling and maxillary sinus pneumatization following tooth loss may represent problems when planning implant-supported

rehabilitation in the posterior maxilla¹. Postextractive bone remodelling leads to significant horizontal and vertical resorption of the edentulous bone crest, and ridge preservation techniques (to maintain adequate three-dimensional bone volume for



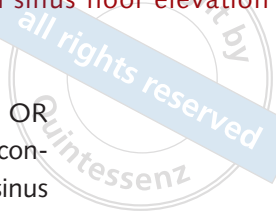implant surgery) are not always effective in limiting this process². When residual bone height is insufficient for implant placement but interarch relationships are still acceptably preserved, sinus floor elevation with lateral approach (LASFE) is a well-tested regenerative option to re-establish adequate crestal height for implant placement^{3,4}. LASFE, derived from the Caldwell-Luc approach^{5,6}, was first proposed by Tatum⁷ and subsequently modified by various authors^{8,9}. After elevating a full-thickness mucoperiosteal flap, a bony window is created on the lateral sinus wall (antrostomy) with a round diamond or carbide bur to access the sinus membrane. The perimeter of the antrostomy is carefully outlined avoiding damaging the underlying membrane, and the bony window is then reflected into the sinus cavity or removed. The sinus membrane is dissected and elevated from the sinus floor and surrounding bone walls using specific manual curettes. This newly created space is subsequently grafted with various biomaterials (originally autogenous bone from the iliac crest^{10,11} and more recently autografts from other intraoral and extraoral sources, allografts, xenografts or alloplasts¹²⁻¹⁷), to promote new bone regeneration and allow insertion of implants of adequate length. Bone substitutes are reliable alternatives to autogenous bone and their use avoids disadvantages related to autografts, including higher morbidity, limited availability and low volumetric stability^{18,19}. Implants inserted after LASFE demonstrated satisfactory clinical outcomes (95% survival rate after 5 years or more of loading²⁰), even if no long-term randomised controlled trials comparing different treatment modalities are present in the literature.

However, LASFE is also associated with a number of intraoperative complications, such as sinus membrane perforation, haemorrhagic events, infra-orbital neurovascular bundle injury, implant dislocation into the sinus cavity and, very infrequently, adjacent teeth devitalisation²¹⁻²³. The sinus membrane perforation is by far the most frequent complication and its occurrence (usually during antrostomy or membrane elevation) is an issue which must be managed by the clinician to complete the intervention and avoid graft

displacement into the sinus cavity²⁴. Rotary instruments, originally proposed to perform antrostomy on the lateral sinus wall⁷⁻¹¹, are associated with a high risk of membrane perforation during this surgical phase (20.4%)²⁴. After a pioneering technical note by Torrella et al²⁵, who described the use of the conventional periodontal ultrasonic generator to perform lateral antrostomy, a novel device specifically designed for piezoelectric bone surgery (PBS) was introduced in this field in 2001²⁶, aiming to reduce the risk of membrane perforation during antrostomy by taking advantage of specific physical characteristics of ultrasonic bone cutting. The micro-vibrations of piezoelectric tips allow extremely precise osteotomies with enhanced surgical control, coupled with selective cutting action of mineralised tissues^{27,28}; these features improved the predictability and decreased complication rates of LASFE.

Many studies with various designs investigating ultrasonic antrostomy have been conducted over the years and a recent systematic review²⁴ showed that the mean incidence of membrane perforation reported in the literature was 10.9% when using piezoelectric surgery. Furthermore, two meta-analyses^{29,30} compared the clinical outcomes of LASFE conducted with rotary instruments or piezoelectric devices. The inclusion criteria adopted in both studies, however, were not particularly restrictive: Atieh et al²⁹ included randomised and non-randomised clinical trials (RCT and CCT), together with retrospective studies in the final analysis; and Jordi et al³⁰ included case series, retrospective and prospective studies (with and without a control group).

The aim of the present systematic review, meta-analysis and trial sequential analysis (TSA) was to analyse the clinical outcomes of LASFE (intraoperative and postoperative complications, surgical time and implant survival rate), comparing the PBS with the use of conventional rotary instruments. The present meta-analysis adopted strict inclusion criteria for study selection (only prospective studies with a control group), and the statistical data reliability in the meta-analysis was quantified by means of TSA (taking into consideration type 1 and 2 errors).



Material and methods

Protocol and search strategy

The present systematic review was conducted in accordance with PRISMA (preferred reporting items for systematic reviews and meta-analyses) guidelines³¹ and registered in the PROSPERO (the international prospective register of systematic reviews) database (www.crd.york.ac.uk/PROSPERO) with registration no. CRD42019122972.

Focus question

The PICO (patient, intervention, comparison and outcome) question that the present systematic review aimed to answer was: “Does PBS for lateral maxillary sinus floor elevation reduce risk of intraoperative complications, require prolonged surgical time and improve the survival rate of dental implants compared with conventional rotary instruments?”.

- Population: patients requiring LASFE to allow dental implants placement
- Intervention: PBS for lateral antrostomy
- Comparison: conventional rotary instruments for lateral antrostomy
- Outcomes: intraoperative complications, implant failure, surgical time.

Information sources

A detailed electronic search was conducted by two independent authors (A.R. and A.E.), who screened, in duplicate, the PubMed, Embase, Scopus and Open Grey databases from 1 January 1990 to the latest entry on 31 December 2018. No language restriction was applied, to limit the selection of bias.

Search

Electronic database searches were performed using the following algorithms:

- PubMed: (piezosurgery OR piezo* OR ultrasonic* OR rotary instrument* OR conventional drill*) AND (sinus lift OR sinus floor elevation OR sinus augmentation OR sinus graft*);

- Embase: ((piezosurgery:ti OR piezo\$:ti OR ultrasonic\$:ti OR 'rota\$ instrument\$':ti OR 'conventional drill\$':ti) AND 'sinus lift\$':ti OR 'sinus floor elevation':ti OR 'sinus augmentation':ti OR 'sinus graft\$':ti) AND [1990-2018]/py;
- Scopus: (piezosurgery OR ultrasonic OR piezoelectric OR rotary) AND (sinus floor elevation OR sinus lift OR sinus augmentation);
- Open Grey: (piezosurgery OR piezoelectric surgery OR ultrasonic surgery OR rotary instrument\$ OR sinus lift\$ OR sinus floor elevation OR sinus augmentation OR sinus graft\$).

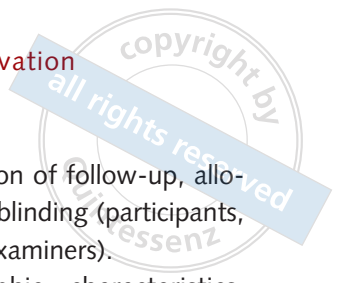Furthermore, references in all selected papers and in previously published systematic reviews on this topic^{24,29,30} were checked for additional studies. The last 5 years (2014 to 2018) of pertinent dental journals (Implant Dentistry, Clinical Oral Implants Research, Clinical Implant Dentistry and Related Research, The International Journal of Oral and Maxillofacial Implants, The International Journal of Periodontics and Restorative Dentistry, Journal of Clinical Periodontology, British Journal of Oral and Maxillofacial Surgery, Journal of Cranio-maxillofacial Surgery, Journal of Oral Implantology, and Journal of Periodontology) were hand searched to identify any potentially relevant paper.

Selection of studies

Two blinded independent authors (F.B. and G.T.) performed, in duplicate, a study eligibility assessment. Intraexaminer reliability in the study selection process was assessed using the Cohen's κ test, assuming a threshold value of 0.61³². Conflicts were resolved by discussion of each article until reaching consensus. Attempts to contact corresponding authors of the included studies were made to retrieve any missing information or clarify specific items.

Types of studies

The present systematic review included only prospective studies conducted on human subjects. Both reviews and studies of lower quality within the hierarchy of scientific evidence (such as expert



opinions, letters, case reports, case series and retrospective studies) were excluded.

Studies were evaluated for selection according to the following criteria:

- Inclusion criteria: randomised controlled trials (RCTs) and case-control studies (CCTs) (≥ 10 patients/group) comparing the PBS with conventional rotary instruments in lateral sinus augmentation and reporting intraoperative and postoperative outcomes (e.g. sinus membrane perforations, bleeding events, surgical time and implant failure rate) for both groups.
- Exclusion criteria: meta-analyses, systematic and narrative reviews, RCTs and CCTs with less than 10 patients per group, retrospective studies, case series, case reports, ex vivo, in vitro and animal studies were excluded. Studies without a control group, or with a different comparison than the antrostomy technique, or providing insufficient data (antrostomy technique not clearly described; no clear mention of intraoperative complications) were also excluded.

Sequential search strategy

Following the initial literature search, all articles were screened to eliminate irrelevant publications, in vitro and animal studies, case reports, case series, retrospective studies and review articles. Studies were screened further based on relevance of data reported in abstracts. Finally, the full texts of the selected papers were examined to confirm study eligibility, following the inclusion and exclusion criteria.

Data extraction

Two authors (C.S. and T.L.) using predefined forms independently extracted the following information from the selected studies:

- Study characteristics: title, authors' names, corresponding author nationality, language of publication, year of publication, journal name, journal impact factor (IF) in the year of publication, ethics committee/institutional review board approval, source of study funding, study design (parallel group or split-mouth), method

of randomisation, duration of follow-up, allocation concealment and blinding (participants, investigators, outcome examiners).

- Participants: demographic characteristics, health condition of participants, smoking status, number of participants in test and control groups, number of and reasons for dropouts.
- Intervention: use of PBS for LASFE – type of piezoelectric device, membrane elevation technique, type of grafting material, number of inserted implants.
- Comparison: use of conventional rotary instruments for LASFE – membrane elevation technique, type of grafting material, number of inserted implants.
- Outcomes: (1) intraoperative biological complications (e.g. membrane perforation, bleeding events) and postoperative complications, including implant failure; (2) surgical time.

Attempts to contact the corresponding authors of the included studies were made to retrieve any missing information or clarify specific items.

Assessment of risk of bias in individual studies

Two reviewers (C.S. and F.B.) independently assessed the risk of bias in the selected studies using the Cochrane Collaboration's tool for risk of bias assessment³³. The analysis was based on the evaluation of six items (random sequence generation, allocation concealment, blinding of outcome assessment, incomplete outcome data, selective reporting and other sources of bias). Studies were then classified into (a) studies with low risk of bias when all criteria were met, (b) studies with unclear risk of bias when one or more criteria were partially met, or (c) studies with high risk of bias when one or more criteria were not met.

Assessment of risk of bias across studies

Heterogeneity was assessed using the χ^2 -based Q-statistic method with a significant *P* value < 0.05 . However, due to the relative insensitivity of the Q statistic³⁴, an *I*² index was also reported with

values $\geq 50\%$ considered to be associated with the substantial heterogeneity of the studies³⁵. In particular, the I^2 index describes the percentage of total variation across studies due to heterogeneity rather than chance. The Review Manager software (version 5.2.6, <http://www.cochrane.org>) was used for the heterogeneity assessment.

Data synthesis

The membrane perforation rate in the test and control groups was pooled by calculating the risk ratio (RR) and its 95% confidence interval (CI), while the surgical procedure duration data were meta-analysed, computing a mean difference (MD) between the procedures analysed. A fixed- or a random-effect model was used based on the presence of heterogeneity (calculated as mentioned above). In the meta-analysis, both cross-over and parallel studies were pooled assuming the absence of the carry-over effect between different interventions performed on the same patient. The overall effects were compared using the inverse of variance test setting $P < 0.05$ as the threshold of statistical significance. In addition, a TSA was performed to adjust the results for the presence of type 1 and 2 statistical errors and analyse the power of available evidence (Trial Sequential Analysis v0.9 β , Copenhagen Trial Unit, Copenhagen, Denmark). Specifically, a type 1 error of 5% and a power of 80% (type 2 error = 80%) were set to calculate trial sequential monitoring boundaries, futility boundaries and the required information size (RIS). A graphical evaluation was performed to analyse whether the Z-curve (showing the treatment effect) crossed one or more of these thresholds.

Results

Description of studies

A total of 1345 articles (in English, German, Chinese, Italian, French, Japanese, Korean, Russian and Romanian) resulted from the initial search (147 from PubMed, 985 from Embase, 108 from Scopus,

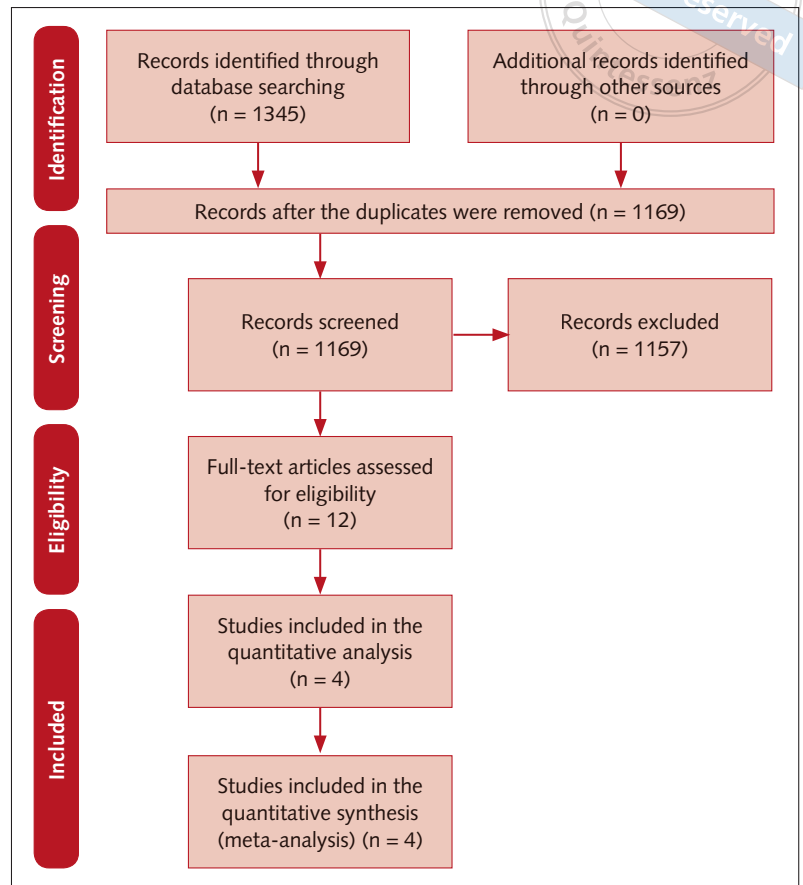
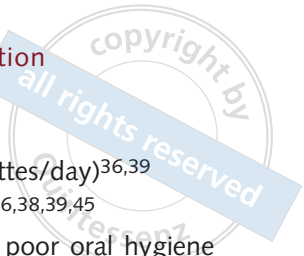

Fig 1 Flowchart of the search process.

105 from Open Grey and none from other sources). After removing duplicates, 1169 titles were examined and 1157 were excluded after reviewing the abstracts (Cohen's κ test for inter-reviewer agreement = 0.91). Twelve articles were downloaded in full text³⁶⁻⁴⁷ and four studies^{36,38,39,45}, matching the inclusion and exclusion criteria, were included in the final analysis (Cohen's κ test for inter-reviewer agreement = 1). The results from the electronic and manual searches are summarised in Figure 1. The list of excluded studies and reasons for exclusion are provided in Table 1. Three studies^{36,38,45} out of four were RCTs with split-mouth design, and one³⁹ was a parallel-group RCT. The authors of one trial³⁸ declared that the study was self-funded, whilst no information about funding was present in the other three articles^{36,39,45}. Only one³⁹ of the included studies reported Ethics Committee approval. The complete characteristics of the included studies are summarised in Table 2.

**Table 1** Reasons for excluding individual studies

Reference	Reason
Lomartire et al (2011) ³⁷	Less than 10 patients per group
Seoane et al (2013) ⁴⁰	Animal study
Weitz et al (2014) ⁴¹	Retrospective study
von Arx et al (2014) ⁴²	Retrospective study
Stacchi et al (2015) ⁴³	Lack of control group with rotary instruments
Geminiani et al (2015) ⁴⁴	Retrospective study
Guerrero (2015) ⁴⁶	No case-control study
Stacchi et al (2017) ⁴⁷	Lack of control group with rotary instruments

Patient characteristics

The sample size in the single studies ranged from a minimum of 12⁴⁵ to a maximum of 36³⁸ patients. The total number of treated patients was 82 (39 females, 31 males and 12 not specified). One study⁴⁵ did not report the sex distribution. The age range varied from 31³⁹ to 76³⁸ years old. One study⁴⁵ did not report the age of the patients.

Patients were enrolled in the individual studies according to the following criteria:

Inclusion criteria

- healthy patients^{36,39}
- residual bone height < 5 mm^{39,45}
- class V (flat ridge form, inadequate in height and width)³⁶ or V-VI (extreme atrophy with depressed ridge form)³⁸ according to the Cawood and Howell⁴⁸ classification
- totally³⁸ or partially^{36,45} edentulous patients
- need of bilateral^{36,38,45} or unilateral/bilateral³⁹ sinus augmentation.

Exclusion criteria

- history of systemic diseases that contraindicate surgical treatment^{36,45}
- history of radiotherapy in the head and neck region^{38,45}
- immunosuppressed or immunocompromised⁴⁵
- uncontrolled diabetes⁴⁵
- use of antibiotics or steroids within 30 days before surgery³⁹
- treated or undergoing treatment with intravenous aminobisphosphonates⁴⁵
- pregnant or nursing⁴⁵
- substance abusers, psychiatric problems or unrealistic expectations⁴⁵

- heavy smokers (> 10 cigarettes/day)^{36,39}
- maxillary sinus pathologies^{36,38,39,45}
- active periodontitis and/or poor oral hygiene and motivation⁴⁵
- history of reconstructive pre-prosthetic surgery or previous implant surgery³⁸
- lack of opposite occluding dentition/prosthesis in the area intended for implant placement⁴⁵.

Surgical procedures

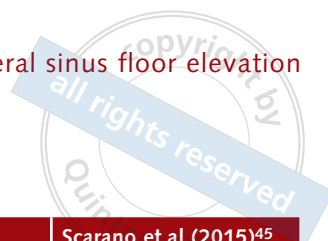A bilateral^{36,38,45} or unilateral³⁹, two-stage LASFE was performed (stage-one, bone grafting; stage-two, implant placement). The PBS was used for lateral antrostomy on the test side and conventional rotary instruments on the control side in all included studies. In both test and control groups of the included studies, the bony window was gently pushed inside the sinus cavity, forming the roof for bone regeneration^{36,38,39,45}. The sinus membrane elevation was completed using manual sinus curettes in both the test and control groups in three studies^{36,38,39}, whilst Scarano et al⁴⁵ used manual curettes in the control group and nasal suction in combination with manual curettes in the test group. The space underneath the elevated membrane was grafted with autogenous bone from the iliac crest³⁸, allograft³⁹ and xenograft³⁶, whilst one study did not report the biomaterial used⁴⁵.

Risk of bias in the individual studies

One study³⁸ was judged to be at low risk of bias after the authors provided additional information not included in the original article. Three studies^{36,39,45} were judged to be at high risk of bias (Table 3).

Complications

The sinus membrane perforation was the only intraoperative complication observed in the four selected studies. In total, nine perforations out of 72 interventions occurred in the PBS group (12.5%) and 12 perforations out of 71 interventions were recorded in the 'rotary instruments' group (16.9%). Two studies described the

**Table 2** Characteristics of the included studies

Characteristics	Barone et al (2008) ³⁶	Rickert et al (2013) ³⁸	Delilbaşı and Gurler (2013) ³⁹	Scarano et al (2015) ⁴⁵	
Study design	RCT (split-mouth)	RCT (split-mouth)	RCT (parallel group)	RCT (split-mouth)	
Country	Italy	Netherlands	Turkey	Italy	
Journal (IF)	Clinical Oral Implants Research (2.756)	Clinical Implant Dentistry and Related Research (3.821)	Implant Dentistry (1.404)	Journal of Craniofacial Surgery (0.700)	
Patients/sinuses	13/26	36/72	21/21	12/24	
PBS	13/13	36/36	11/11	12/12	
CT	13/13	36/36	10/10	12/12	
Mean age (range), years	56.6 (45–67)	59.2 (38–76)	PBS 48.8 (31–66) CT 46.2 (38–51)	NR	
Antrostomy technique	Bone window pushed inside the sinus cavity	Bone window pushed inside the sinus cavity	Bone window pushed inside the sinus cavity	Bone window pushed inside the sinus cavity	
Piezoelectric device	Piezosurgery Mectron, Italy	Piezosurgery Mectron, Italy	Piezon Master EMS, Switzerland	Surgysonic, Esacrom, Italy	
Conventional instruments	DB	DB	DB, osteotomes and mallets	DB	
Membrane elevation	MSC	MSC	MSC	PBS: nasal suction/MSCT CT: MSC	
Grafting material	Xenograft	Autologous	Allograft	NR	
Membrane perforation rate (%)	PBS	30.8	11.1	9.1	0
	CT	23.1	11.1	10	33.3
Surgical duration (min)	PBS	11.5 ± 3.8	15.1 ± 2.9	20.2 ± 8.6	NR
	CT	10.2 ± 2.4	11.1 ± 2.4	18.0 ± 8.2	NR
Implant failure rate (%)	PBS	NR	0	NR	NR
	CT	NR	0	NR	NR

CT, conventional technique; DB, diamond burs; IF, impact factor; MSC, manual sinus curettes; NR, not reported; PBS, piezoelectric bone surgery; RCT, randomised clinical trial.

Table 3 Risk of bias among individual studies

	Barone et al (2008) ³⁶	Rickert et al (2013) ³⁸	Delilbaşı and Gurler (2013) ³⁹	Scarano et al (2015) ⁴⁵
Random sequence generation	Low risk; reported in the article as "computer-generated randomization list"	Low risk; reported in the article as "by envelopes"	Unclear; insufficient information	Unclear; insufficient information
Allocation concealment	Low risk; reported in the article as "An independent evaluator distributed the test and control sites..."	Low risk; the authors replied to a previous reviewer ²⁶ "opaque numbered sealed envelopes"	High risk; NR	High risk; NR
Blinding of outcome assessment*	High risk; the authors replied that "the assessors were not blinded"	Low risk; the authors replied to a previous reviewer ²⁶ "the assessors were blinded"	High risk; NR	High risk; NR
Incomplete outcome data	Low risk; all data presented	Low risk; all data presented	High risk; it is unclear how dropouts influenced outcomes	High risk; 30 patients were randomised, 12 patients received intervention
Selective reporting	Low risk; all outcomes seem to be reported	Low risk; all outcomes seem to be reported	Low risk; all outcomes seem to be reported	Low risk; all outcomes seem to be reported
Other bias	None detected	None detected	None detected	None detected

*The risk of bias for non-blinded operators performing the treatment was not judged as a significant risk of bias. NR, not reported.

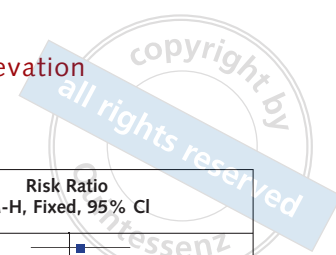


Fig 2 Sinus membrane perforation.

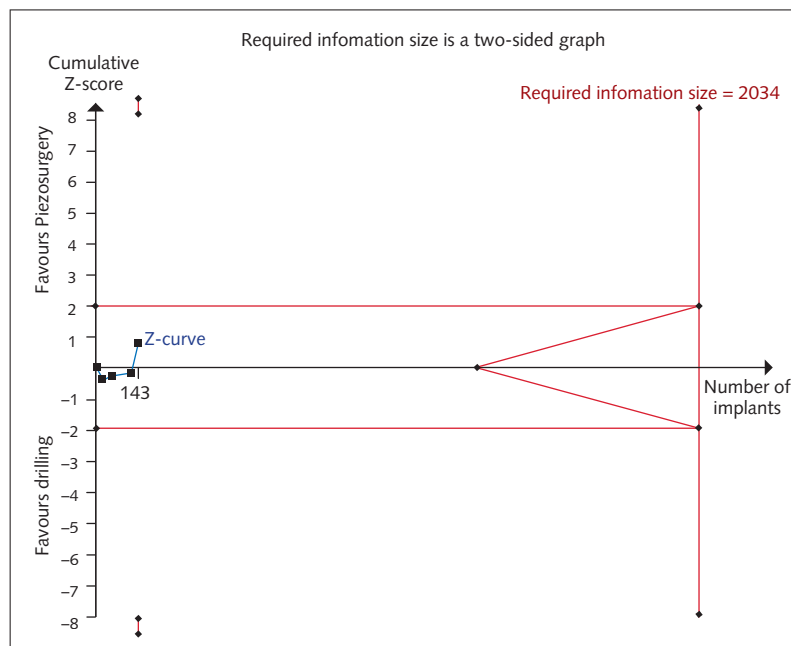
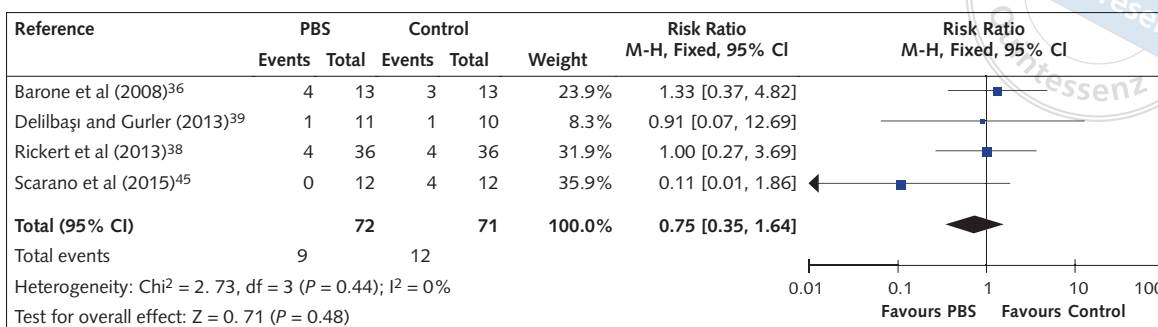


Fig 3 Trial sequential analysis for the variable 'sinus membrane perforation'.

perforation characteristics: Barone et al³⁶ reported four perforations out of 13 interventions using PBS (incidence 30.7%; one perforation larger than 3 mm, three smaller than 2 mm) and three perforations in the control group (incidence 23%; all perforations smaller than 2 mm); and Scarano et al⁴⁵ reported no perforations in 12 interventions when using PBS and four perforations smaller than 5 mm in the control group (33.3%). None of the studies reported when perforations occurred (e.g. during antrostomy, during membrane elevation or during grafting procedure). The meta-analysis revealed no significant differences in terms of membrane perforation rate between test and control group (RR = 0.75; 95% CI = 0.35 to 1.64; $P = 0.48$; Fig 2). No heterogeneity was noted

($I^2 = 0\%$; $df = 3$; $P = 0.44$; $\chi^2 = 2.73$) and therefore a fixed-effect model was used. These results were confirmed by TSA, however, such analysis showed that a much more powered information size (RIS = 2034 interventions, compared with 143 interventions included in the present meta-analysis) was required to draw conclusions about the magnitude of the treatment effect (Fig 3).

No other intraoperative complications were recorded. Two postoperative sinus infections (one in the test group and one in the control group) were reported in one trial³⁹. Implant failure was reported in one study³⁸; the survival rate one year after prosthetic loading was 100%.

Surgical time

Three studies^{36,38,39} recorded the duration of the antrostomy and sinus membrane elevation in both the test and control groups. The mean difference between the two procedures was 3.43 minutes, significantly favouring the control group (95% CI = 2.34 to 4.51; $P < 0.00001$; Fig 4). Some heterogeneity was present across the three included studies ($I^2 = 48\%$; $df = 2$; $P = 0.15$; $\chi^2 = 3.86$); however, as the P value of the Q test was 0.15, a fixed-effect model was used. The TSA confirmed these findings as shown by the Z-curve crossing the lower trial sequential monitoring boundary. In addition, the power was close to the RIS threshold (136 interventions comprised the required sample to have a power of 80% versus 119 interventions included in the present meta-analysis), showing a moderate power of evidence (Fig 5).

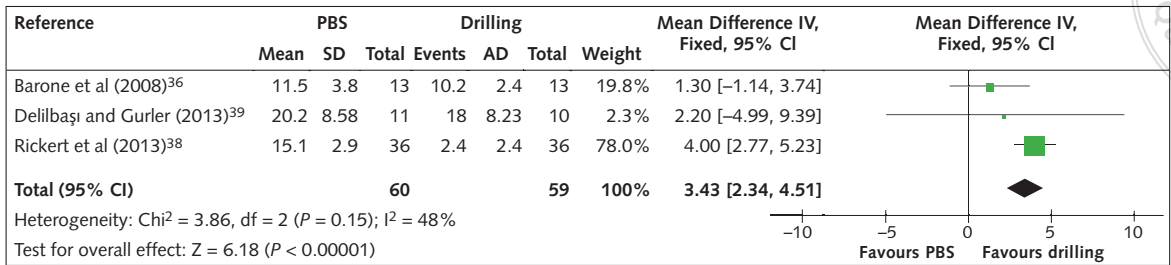
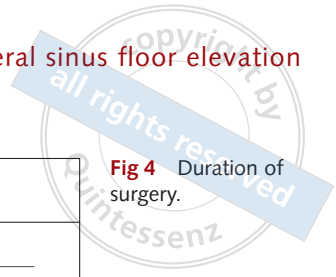


Fig 4 Duration of surgery.

Discussion

Clinical findings

Many clinical applications of PBS have been proposed in the oral and maxillofacial fields, including dental extraction, ridge splitting, implant site preparation, bone harvesting and orthodontic corticotomies⁴⁹⁻⁵⁵. In addition to these, ultrasonic lateral antrostomy for sinus floor elevation has been one of the most popular techniques among clinicians since its introduction²⁶. The ability of piezoelectric devices to selectively cut mineralised tissues has been considered an important feature, possibly reducing the risk of the most common intraoperative complication in LASFE, namely the sinus membrane perforation. This represents an important factor to improve the clinical outcomes of the procedure. A recent meta-analysis⁵⁶ demonstrated that membrane tearing significantly affects post-operative sinusitis after implant surgery.

Three main surgical techniques are possible when using PBS in LASFE: (i) lateral bone window outlining and subsequent reflection into the sinus cavity; (ii) window outlining and removal; (iii) consuming the lateral wall until the membrane is visible under a thin layer of bone before outlining the window. Previous reviews and RCTs showed that thinning the lateral wall before window outlining is associated with a lower risk of membrane perforation compared to the other two approaches^{24,43}.

The results of the present systematic review did not support the hypothesis that PBS is safer than the rotary instruments in preventing the sinus membrane perforation. Although a slightly lower incidence of membrane tearing occurred using PBS for lateral antrostomy compared with

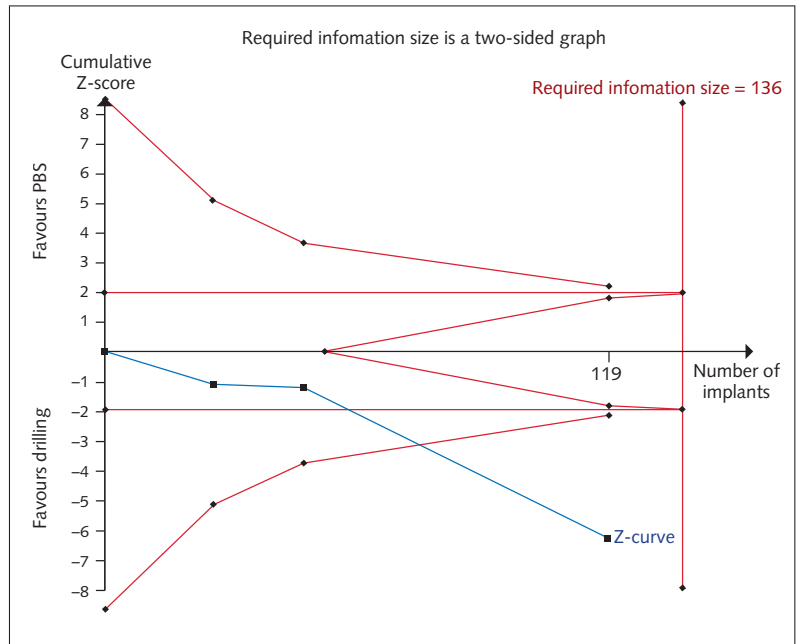
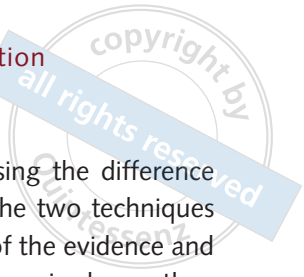

Fig 5 Trial sequential analysis for the variable 'duration of surgery'.

rotary burs, the difference between the two groups was not significant. This outcome is in accordance with a previous meta-analysis by Atieh et al²⁹, but in disagreement with two other recent systematic reviews by Stacchi et al²⁴ and Jordi et al³⁰, in which PBS significantly reduced the incidence of membrane perforation. Some considerations arise from analysing these discrepancies: Stacchi et al²⁴ and Jordi et al³⁰ included a broad number of articles, while the present systematic review and the meta-analysis by Atieh et al²⁹ adopted very strict inclusion criteria, selecting only studies whose primary aim was to compare PBS and rotary instruments solely in terms of intraoperative complications during LASFE. This choice led to the inclusion of a very



limited number of articles in the final analysis. An additional possible bias was the type of ultrasonic approach. In fact, bone window outlining and reflection into the sinus cavity was performed in all four included RCTs. This surgical technique was previously described as the least predictable for piezoelectric antrostomy, resulting in a perforation risk (17.6%) comparable to rotary instruments²⁴. In addition, none of the included RCTs specified the surgical phase in which perforations occurred. If the membrane was damaged during elevation or the grafting procedure it would have been completely independent from the use of PBS or rotary burs.

In the present systematic review, the surgical duration was significantly longer with PBS than with the conventional rotary instruments, according to the meta-analysis by Atieh et al²⁹. However, it remains unclear if the mean difference between the two techniques (approximately 3 minutes and 30 seconds) represents a real clinical advantage for both operator and patient.

Insufficient data (small sample, heterogeneity of grafting materials and missing information on implant survival) did not allow to evaluate the influence that the use of PBS or rotary instruments during antrostomy have on the survival rate of implants inserted following sinus augmentation.

Quality of evidence

Three^{36,39,45} out of four RCTs included in the present systematic review were judged to be at high risk of bias, with the fourth³⁸ at low risk of bias. The TSA conducted for the membrane perforation risk showed that the power of evidence of this meta-analysis was extremely weak. A sample size of 2034 interventions, compared with the 143 interventions included in the present systematic review, was needed to evaluate the magnitude of the treatment effect. Further well-designed clinical trials comparing the most predictable ultrasonic approach (consuming the lateral wall) to conventional rotary instruments and recording the exact moment of membrane perforation are required to draw definitive conclusions on this point.

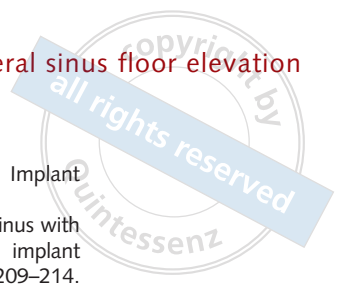
Conversely, the TSA analysing the difference in surgical duration between the two techniques confirmed a moderate power of the evidence and suggested that ultrasonic surgery is slower than the rotary instruments in performing lateral antrostomy. For this specific item, the power of the present meta-analysis was close to the threshold of the required information size (119 included interventions versus 136 interventions necessary for a power of 80%). However, it should also be noted that only three studies were included in the final analysis for this specific outcome^{36,38,39}, with two of them judged at high risk of bias.

Limitations

It should be stated that the strict inclusion criteria adopted in the present meta-analysis increased the study homogeneity but, at the same time, also the risk of excluding significant data⁵⁷. In fact, bone window outlining and reflection into the sinus cavity was performed in all four included RCTs. This surgical technique was previously described as the least predictable for piezoelectric antrostomy, resulting in a perforation risk (17.6%) comparable to rotary instruments²⁴. In addition, none of the included RCTs specified the surgical phase in which perforations occurred. If the membrane was damaged during elevation or the grafting procedure it would have been completely independent from the use of PBS or rotary burs.

None of the included RCTs analysed patient discomfort during and after the procedure; accurate evaluation of intraoperative and postoperative pain and swelling should be performed by future trials to have additional information to choose between the two techniques.

Nevertheless, the methodological approach of the present study could help clarify the real available evidence on this specific topic and may motivate researchers to design appropriate future clinical trials. Hence, the results reported in the present meta-analysis should be interpreted with caution.



Conclusions

Based on the results of the present meta-analysis and TSA to assess if the piezoelectric bone surgery for lateral maxillary sinus floor elevation reduces the risk of intraoperative complications, prolongs surgery duration and improves the survival rate of dental implants compared with conventional rotary instruments, the following conclusions can be drawn:

- There was weak evidence suggesting that there is no difference in membrane perforation risk between piezoelectric surgery and rotary instruments;
- There was moderate evidence suggesting that piezoelectric surgery prolongs surgery duration when compared with rotary instruments;
- There were insufficient data to assess if piezoelectric surgery in lateral sinus floor elevation improves the survival rate of dental implants inserted in augmented sinuses, when compared with conventional rotary instruments.

Further well-designed, adequately powered randomised clinical trials are necessary to improve the level of evidence on this topic.

References

1. Farina R, Pramstraller M, Franceschetti G, Pramstraller C, Trombelli L. Alveolar ridge dimensions in maxillary posterior sextants: a retrospective comparative study of dentate and edentulous sites using computerized tomography data. *Clin Oral Implants Res* 2011;22:1138–1144.
2. Lombardi T, Bernardello F, Berton F, et al. Efficacy of alveolar ridge preservation after maxillary molar extraction in reducing crestal bone resorption and sinus pneumatization: A multicenter prospective case-control study. *Biomed Res Int* 2018;2018:9352130.
3. Beretta M, Poli PP, Grossi GB, Pieroni S, Maiorana C. Long-term survival rate of implants placed in conjunction with 246 sinus floor elevation procedures: results of a 15-year retrospective study. *J Dent* 2015;43:78–86.
4. Park WB, Kang KL, Han JY. Factors influencing long-term survival rates of implants placed simultaneously with lateral maxillary sinus floor augmentation: A 6- to 20-year retrospective study. *Clin Oral Implants Res* 2019;30:977–988.
5. Caldwell GW. Diseases of the accessory sinuses of the nose and an improved method of treatment of suppuration of the maxillary antrum. *New York Med J* 1893;58:526–528.
6. Luc H. Une nouvelle méthode opératoire pour la cure radicale et rapide de l'empyème chronique du sinus maxillaire. *Arch Int Laryngol Otol Rhinol* 1897;10:273–285.
7. Tatum OH. Lecture presented at the Alabama Implant Congress. 1976.
8. Wood RM, Moore DL. Grafting of the maxillary sinus with intraorally harvested autogenous bone prior to implant placement. *Int J Oral Maxillofac Implants* 1988;3:209–214.
9. Smiler DG. The sinus lift graft: basic technique and variations. *Pract Periodontics Aesthet Dent* 1997;9:885–893.
10. Boyne PJ, James RA. Grafting of the maxillary sinus floor with autogenous marrow and bone. *J Oral Surg* 1980;38:613–616.
11. Tatum H Jr. Maxillary and sinus implant reconstructions. *Dent Clin North Am* 1986;30:207–229.
12. Deppe H, Mücke T, Wagenpfeil S, Hölzle F. Sinus augmentation with intra- vs extraorally harvested bone grafts for the provision of dental implants: clinical long-term results. *Quintessence Int* 2012;43:469–481.
13. Maddalone M, Mirabelli L, Venino PM, Karanxha L, Porcaro G, Del Fabbro M. Long-term stability of autologous bone graft of intraoral origin after lateral sinus floor elevation with simultaneous implant placement. *Clin Implant Dent Relat Res* 2018;20:713–721.
14. Kolerman R, Nissan J, Rahmanov M, Vered H, Cohen O, Tal H. Comparison between mineralized cancellous bone allograft and an alloplast material for sinus augmentation: a split mouth histomorphometric study. *Clin Implant Dent Relat Res* 2017;19:812–820.
15. Stacchi C, Berton F, Fiorillo L, et al. Fresh frozen allogeneic bone block in maxillary sinus floor elevation: histomorphometric analysis of a bone specimen retrieved 15 years after grafting procedure. *Appl Sci* 2019;9:1119.
16. Stacchi C, Lombardi T, Oreglia F, Alberghini Maltoni A, Traini T. Histologic and histomorphometric comparison between sintered nanohydroxyapatite and anorganic bovine xenograft in maxillary sinus grafting: a split-mouth randomized controlled clinical trial. *Biomed Res Int* 2017;2017:9489825.
17. Galindo-Moreno P, de Buitrago JG, Padiál-Molina M, Fernández-Barbero JE, Ata-Ali J, O Valle F. Histopathological comparison of healing after maxillary sinus augmentation using xenograft mixed with autogenous bone versus allograft mixed with autogenous bone. *Clin Oral Implants Res* 2018;29:192–201.
18. Danesh-Sani SA, Engebretson SP, Janal MN. Histomorphometric results of different grafting materials and effect of healing time on bone maturation after sinus floor augmentation: a systematic review and meta-analysis. *J Periodontol Res* 2017;52:301–312.
19. Starch-Jensen T, Mordenfeld A, Becktor JP, Jensen SS. Maxillary sinus floor augmentation with synthetic bone substitutes compared with other grafting materials: a systematic review and meta-analysis. *Implant Dent* 2018;27:363–374.
20. Starch-Jensen T, Aludden H, Hallman M, Dahlin C, Christensen AE, Mordenfeld A. A systematic review and meta-analysis of long-term studies (five or more years) assessing maxillary sinus floor augmentation. *Int J Oral Maxillofac Surg* 2018;47:103–116.
21. Chanavaz M. Sinus graft procedures and implant dentistry: a review of 21 years of surgical experience (1979–2000). *Implant Dent* 2000;9:197–206.
22. Zijdeveld SA, van den Bergh JP, Schulten EA, ten Bruggenkate CM. Anatomical and surgical findings and complications in 100 consecutive maxillary sinus floor elevation procedures. *J Oral Maxillofac Surg* 2008;66:1426–1438.
23. Beck F, Lauterbrunner N, Lettner S, Stavropoulos A, Ulm C, Bertl K. Devascularization of adjacent teeth following maxillary sinus floor augmentation: a retrospective radiographic study. *Clin Implant Dent Relat Res* 2018;20:763–769.



24. Stacchi C, Andolsek F, Berton F, Perinetti G, Navarra CO, Di Lenarda R. Intraoperative complications during sinus floor elevation with lateral approach: a systematic review. *Int J Oral Maxillofac Implants* 2017;32:e107–e118.
25. Torrella F, Pitarch J, Cabanes G, Anitua E. Ultrasonic osteotomy for the surgical approach of the maxillary sinus: a technical note. *Int J Oral Maxillofac Implants* 1998;13:697–700.
26. Vercellotti T, De Paoli S, Nevins M. The piezoelectric bony window osteotomy and sinus membrane elevation: introduction of a new technique for simplification of the sinus augmentation procedure. *Int J Periodontics Restorative Dent* 2001;21:561–567.
27. Schaeren S, Jaquiéry C, Heberer M, Tolnay M, Vercellotti T, Martin I. Assessment of nerve damage using a novel ultrasonic device for bone cutting. *J Oral Maxillofac Surg* 2008;66:593–596.
28. Stacchi C, Berton F, Turco G, et al. Micromorphometric analysis of bone blocks harvested with eight different ultrasonic and sonic devices for osseous surgery. *J Cranio-maxillofac Surg* 2016;44:1143–1151.
29. Atieh MA, Alsabeeha NH, Tawse-Smith A, Faggion CM Jr, Duncan WJ. Piezoelectric surgery vs rotary instruments for lateral maxillary sinus floor elevation: a systematic review and meta-analysis of intra- and postoperative complications. *Int J Oral Maxillofac Implants* 2015;30:1262–1271.
30. Jordi C, Mukaddam K, Lambrecht JT, Kühl S. Membrane perforation rate in lateral maxillary sinus floor augmentation using conventional rotating instruments and piezoelectric device – a meta-analysis. *Int J Implant Dent* 2018;4:3.
31. Moher D, Liberati A, Tetzlaff J, Altman DG; PRISMA Group. Preferred reporting items for systematic reviews and meta-analyses: the PRISMA statement. *J Clin Epidemiol* 2009;62:1006–1012.
32. Landis JR, Koch GG. The measurement of observer agreement for categorical data. *Biometrics* 1977;33:159–174.
33. Higgins JPT, Green S (editors). *Cochrane Handbook for Systematic Reviews of Interventions*, version 5.1.0 (updated March 2011). Cochrane Collaboration. Available from www.cochrane.org/training/cochrane-handbook (Accessed: 22 April 2019)
34. Lau J, Ioannidis JP, Schmid CH. Quantitative synthesis in systematic reviews. *Ann Intern Med* 1997;127:820–826.
35. Higgins JP, Thompson SG. Quantifying heterogeneity in a meta-analysis. *Stat Med* 2002;21:1539–1558.
36. Barone A, Santini S, Marconcini S, Giacomelli L, Gherlone E, Covani U. Osteotomy and membrane elevation during the maxillary sinus augmentation procedure. A comparative study: piezoelectric device vs. conventional rotative instruments. *Clin Oral Implants Res* 2008;19:511–515.
37. Lomartire G, Carini F, Santagada V, Pirrone F, Bonacina G. Maxillary sinus lift with collection of an autologous bone graft from an intraoral site: piezoelectric surgery vs traditional surgery. *Italian Oral Surg* 2012;11:S174–S186.
38. Rickert D, Vissink A, Slater JJ, Meijer HJ, Raghoobar GM. Comparison between conventional and piezoelectric surgical tools for maxillary sinus floor elevation. A randomized controlled clinical trial. *Clin Implant Dent Relat Res* 2013;15:297–302.
39. Delilbaşı C, Gurler G. Comparison of piezosurgery and conventional rotative instruments in direct sinus lifting. *Implant Dent* 2013;22:662–665.
40. Seoane J, López-Niño J, García-Caballero L, Seoane-Romero JM, Tomás I, Varela-Centelles P. Membrane perforation in sinus floor elevation – piezoelectric device versus conventional rotary instruments for osteotomy: an experimental study. *Clin Implant Dent Relat Res* 2013;15:867–873.
41. Weitz DS, Geminiani A, Papadimitriou DE, Ercoli C, Caton JG. The incidence of membrane perforation during sinus floor elevation using sonic instruments: a series of 40 cases. *Int J Periodontics Restorative Dent* 2014;34:105–112.
42. von Arx T, Satta IF, Bornstein M, Jensen SS. Perforation of the sinus membrane during sinus floor elevation: a retrospective study of frequency and possible risk factors. *Int J Oral Maxillofac Implants* 2014;29:718–726.
43. Stacchi C, Vercellotti T, Toschetti A, Speroni S, Salgarello S, Di Lenarda R. Intraoperative complications during sinus floor elevation using two different ultrasonic approaches: a two-center, randomized, controlled clinical trial. *Clin Implant Dent Relat Res* 2015;17:e117–e125.
44. Geminiani A, Weitz DS, Ercoli C, Feng C, Caton JG, Papadimitriou DE. A comparative study of the incidence of Schneiderian membrane perforations during maxillary sinus augmentation with a sonic oscillating handpiece versus a conventional turbine handpiece. *Clin Implant Dent Relat Res* 2015;17:327–334.
45. Scarano A, Mavriqi L, Bertelli I, Mortellaro C, Di Cerbo A. Occurrence of maxillary sinus membrane perforation following nasal suction technique and ultrasonic approach versus conventional technique with rotary instruments. *J Craniofac Surg* 2015;26:706–708.
46. Guerrero JS. Lateral window sinus augmentation: complications and outcomes of 101 consecutive procedures. *Implant Dent* 2015;24:354–361.
47. Stacchi C, Lombardi T, Cusimano P, et al. Bone scrapers versus piezoelectric surgery in the lateral antrostomy for sinus floor elevation. *J Craniofac Surg* 2017;28:1191–1196.
48. Cawood JI, Howell RA. A classification of edentulous jaws. *Int J Oral Maxillofac Surg* 1988;17:232–236.
49. Spinato S, Rebaudi A, Bernardello F, Bertoldi C, Zaffe D. Piezosurgical treatment of crestal bone: quantitative comparison of post-extractive socket outcomes with those of traditional treatment. *Clin Oral Implants Res* 2016;27:361–366.
50. Nguyen VG, von Krockow N, Weigl P, Depprich R. Lateral alveolar ridge expansion in the anterior maxilla using piezoelectric surgery for immediate implant placement. *Int J Oral Maxillofac Implants* 2016;31:687–699.
51. Stacchi C, Lombardi T, Baldi D, et al. Immediate loading of implant-supported single crowns after conventional and ultrasonic implant site preparation: a multicenter randomized controlled clinical trial. *Biomed Res Int* 2018;2018:6817154.
52. Stacchi C, De Biasi M, Torelli L, Robiony M, Di Lenarda R, Angerame D. Primary stability of short implants inserted using piezoelectric or drilling systems: an in vitro comparison. *J Oral Implantol* 2019;45:259–266.
53. Valente NA, Cosma L, Nocca G, D’Addona A, Lajolo C. Piezoelectric device versus conventional osteotomy instruments in the comparison of three different bone harvesting methods: An istomorphometric, phonometric, and chronometric evaluation. *Int J Oral Maxillofac Implants* 2019;34:1070–1077.
54. Finotti M, Gracco A, Del Torre M, Siviero L, de Stefani A, Bruno G. The use of computer-assisted corticotomy to enhance surgical procedures. *Int Orthod* 2017;15:498–514.
55. Stacchi C, Chen ST, Raghoobar GM, et al. Malpositioned osseointegrated implants relocated with segmental osteotomies: a retrospective analysis of a multicenter case series with a 1- to 15-year follow-up. *Clin Implant Dent Relat Res* 2013;15:836–846.

56. Kim JS, Choi SM, Yoon JH, et al. What affects postoperative sinusitis and implant failure after dental implant: A meta-analysis. *Otolaryngol Head Neck Surg* 2019;160:974–984.
57. Shrier I, Boivin JF, Steele RJ, et al. Should meta-analyses of interventions include observational studies in addition to randomized controlled trials? A critical examination of underlying principles. *Am J Epidemiol* 2007;166:1203–1209.



Claudio Stacchi

Claudio Stacchi, DDS, MSc

Department of Medical, Surgical and Health Sciences, University of Trieste, Trieste, Italy

Giuseppe Troiano, DDS, PhD

Department of Clinical and Experimental Medicine, University of Foggia, Foggia, Italy

Federico Berton, DDS, MSc, PhD

Department of Medical, Surgical and Health Sciences, University of Trieste, Trieste, Italy

Teresa Lombardi, DDS

Department of Health Sciences, University of "Magna Græcia", Catanzaro, Italy

Antonio Rapani, DDS, MSc

Department of Medical, Surgical and Health Sciences, University of Trieste, Trieste, Italy

Andrea Englaro, DDS

Department of Medical, Surgical and Health Sciences, University of Trieste, Trieste, Italy

Fabio Galli, MD, DDS

Department of Biomedical, Surgical and Dental Sciences, University of Milan, Milan, Italy

Tiziano Testori, MD, DDS, FICD

Department of Biomedical, Surgical and Dental Sciences, University of Milan, Milan, Italy; Department of Periodontics and Oral Medicine, University of Michigan, Ann Arbor, USA

Myron Nevins, DDS

Department of Oral Medicine, Infection and Immunity, Harvard University, Boston, USA

Correspondence to:

Claudio Stacchi, Department of Medical, Surgical and Health Sciences, University of Trieste, Corso Italia 121, 34170 Gorizia, Italy. Email: claudio@stacchi.it

Literature abstract

Dent Mater 2020;36:1–8.

Sadowsky SJ. Has zirconia made a material difference in implant prosthodontics? A review

Objective: The main goal of this review is to provide an in-depth description of published work on the application of zirconia for dental implants and restorations on titanium implants, with an emphasis on clinical studies from the past dozen years with at least 1-year follow-up. **Methods:** Online databases (Pubmed, Science Direct, Web of Science) were consulted on this topic. Published work from 2007 to 2019 was collected, analyzed and pertinent articles were selected for inclusion on this review. **Results:** No clear superiority has been documented in biocompatibility, osteoconductivity, physical properties or allergenicity with zirconia implants compared to titanium, notwithstanding an esthetic benefit. While short-term studies have been promising, larger multicentered, longitudinal and randomized clinical trials with success data are required to validate zirconia as a viable alternative to the titanium implant and its design. Zirconia abutments with a titanium base have revealed a high survival rate and show no difference to metal. Bi-layered zirconia ceramic restorations are a valid treatment alternative to metal ceramic implant restorations for single crowns with similar biological complications and enhanced esthetics. Monolithic zirconia restorations hold promise to address the chipping incidence of the bi-layered ceramic restoration, but longer-term studies are necessary, and work needs to be done to improve their esthetics. The gingival feldspathic porcelain veneered monolithic zirconia complete arch prosthesis versus a resin metal prosthesis, in medium-term studies, offers a high survival rate and low mechanical complication rate, reduced laboratory costs, superior durability and wear characteristics, enhanced fit due to digital fabrication, availability of a digital file for duplication in the future, acrylic try-for adjustment and approval, and reduced plaque and biofilm accumulation. **Significance:** Zirconia is a versatile material for implant prosthodontic application. Longer-term multi-centered studies are needed to assess success criteria and patient-related outcomes measurements. Monolithic zirconia offers enhanced mechanical properties for implant restorations, but development is needed to optimize esthetics. **Correspondence to:** ssadowsky@pacific.edu, Copyright © 2019. Published by Elsevier Inc.