

# Bone Scrapers Versus Piezoelectric Surgery in the Lateral Antrostomy for Sinus Floor Elevation

Claudio Stacchi, DDS, MSc,\* Teresa Lombardi, DDS,† Paolo Cusimano, DDS,‡  
 Federico Berton, DDS, MSc,\* Floriana Lauritano, DDS, PhD,§ Gabriele Cervino, DDS, PhD,§  
 Roberto Di Lenarda, DDS, MSc,\* and Marco Cicciù, DDS, MSc§

**Abstract:** The purpose of this investigation is to evaluate 2 different methods for reducing cortical wall thickness in sinus floor augmentation surgery. A manual bone scraper was compared in terms of efficacy, speed, and safety to an ultrasonic insert for osteoplasty, in a randomized controlled clinical trial with a split-mouth design. Twenty-five patients with severe posterior maxillary atrophy were treated with bilateral sinus floor elevation with lateral approach. Antrostomies were randomly performed by eroding the cortical wall with a manual bone scraper (test site) or with an ultrasonic insert (control site) until the membrane was visible under a thin layer of bone, before outlining the window with a piezoelectric device. Occurrence of membrane perforation, laceration of vascular branches, and surgical time were recorded. Mean surgical time of the antrostomy in the test sites was 9'18", while in the control sites was 9'47". No significant differences were found in terms of surgical time, incidence of membrane perforation during antrostomy (4.3% in both groups), or other intraoperative complications between the 2 techniques. Both surgical approaches represent effective options for performing lateral antrostomies during sinus floor elevation procedures in a safe and predictable way.

**Key Words:** Bone scrapers, membrane perforation, piezosurgery, sinus lift

(*J Craniofac Surg* 2017;00: 00–00)

One augmentation procedure of the jaws is a challenge for clinicians and surgeons. Even though the regenerative technique for managing horizontal and vertical defects of the atrophic ridge is today considered predictable and safe, the postoperative discomfort still remains an unsolved problem. The maxillary areas requiring regenerative procedures are a consequence of tooth loss

and, sometimes, of an improper surgical and prosthetic management.<sup>1–3</sup>

The maxillary sinus is an anatomical structure that is often involved in several maxillofacial surgical procedures in the posterior maxilla, and whose integrity is important to be preserved. Infraction or invasion of this anatomical cavity can happen during surgical procedures and implant placement, especially when residual ridge height is reduced due to the bone remodeling and resorption following tooth extractions. The invasion of the maxillary sinus could hypothetically be considered a potential source of infection or irritation, which could lead to inflammation of sinus membrane.<sup>1,3–5</sup>

Various surgical techniques have been proposed to regenerate an adequate bone volume and allow subsequent dental implants placement.<sup>2–6</sup> Due to the improvement of surgical techniques and the progress of research in the field of dental biomaterials, predictable and safe outcomes can be expected today for implant-supported dental rehabilitations even in cases with severely atrophic ridges.<sup>3,4–7</sup>

Sinus augmentation has then evolved into a predictable and widespread surgical modality for increasing the existing crestal height with bone of sufficient quality to allow predictable positioning and long-term survival of dental implants.<sup>3–10</sup> This surgery is a relatively safe procedure, but several complications may occur as a consequence of inadequate surgical planning or related to aggressive or improper surgical manoeuvres. In the attempt to overcome these obstacles, many alternative procedures have been proposed and introduced into the clinical practice over the years.<sup>2,8,10</sup>

Main intraoperative complications of sinus augmentation with lateral approach were described, such as fractures of residual alveolar ridge, damage to adjacent teeth, and hemorrhagic problems, as an anastomosis between posterior superior alveolar artery and infraorbital artery is always present in the lateral sinus wall area. Damage to this artery may occur during antrostomy, causing profuse bleeding and difficulties in completing surgical procedure: its course should be evaluated in the presurgical planning to limit the occurrence of this complication.<sup>1–5</sup>

Antrostomy was traditionally performed using rotary instruments, with a mean membrane perforation rate of around 20%: lately, the introduction of piezoelectric devices for lateral window preparation and membrane separation led to a significant reduction in the occurrence of the intraoperative complications of bleeding and membrane perforation.<sup>8,9</sup>

Recently, the use of manual bone scrapers has been proposed as a safe and predictable approach to consume the lateral wall of the sinus before performing the antrostomy but this technique has not been compared yet to others in a prospective study.<sup>11,12</sup>

The aim of this randomized clinical trial with a split-mouth design was to analyze 2 different methods for reducing cortical wall

From the \*Department of Medical, Surgical and Health Sciences, University of Trieste, Trieste; †Private Practice, Cassano allo Ionio; ‡Private Practice, Palermo; and §Department of Biomedical and Dental Sciences, Morphological and Functional Images, School of Dentistry, University of Messina, Messina, Italy.

Received December 3, 2016.

Accepted for publication December 29, 2016.

Address correspondence and reprint requests to Prof Marco Cicciù, DDS, MSc, PhD, Department of Biomedical and Dental Sciences, Morphological and Functional Images, School of Dentistry, University of Messina, Messina, Italy;

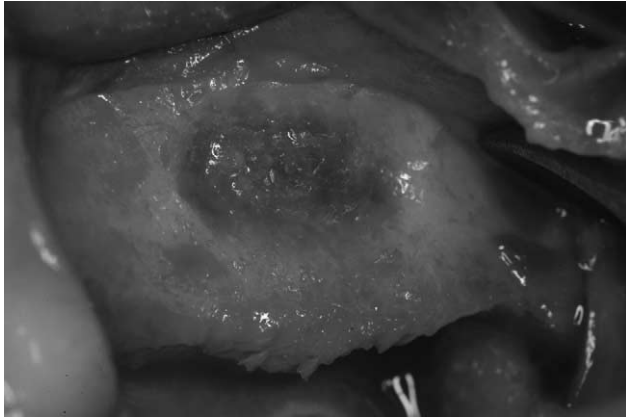
E-mail: acromarco@yahoo.it; mcicciu@unime.it

The authors report no conflicts of interest.

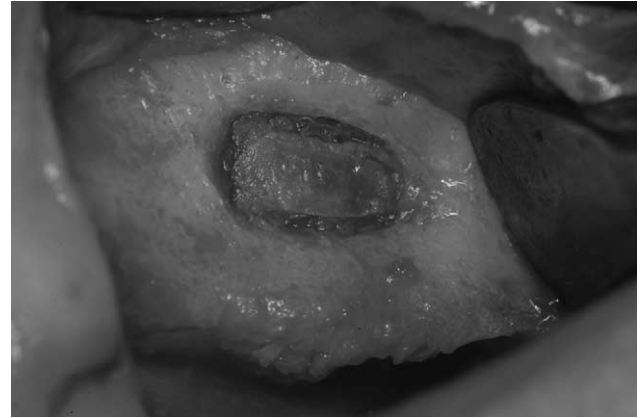
Copyright © 2017 by Mutaz B. Habal, MD

ISSN: 1049-2275

DOI: 10.1097/SCS.0000000000003636



**FIGURE 1.** Erosion of the lateral wall of the maxillary sinus was performed until the Schneiderian membrane appeared evident under a thin bone layer.



**FIGURE 2.** Window perimeter was outlined with ultrasonic instruments to complete the anrostomy.

thickness before outlining the window in sinus floor elevation: a manual bone scraper was compared, in terms of efficacy, speed, and safety to an ultrasonic insert for osteoplasty.

**METHODS**

**Study Design**

This study was a 2-center, randomized controlled clinical trial with balanced randomization (1:1), conducted by 2 experienced operators (CS and TL), who enrolled and treated patients from January to September 2016.

The research was conducted in accordance with the recommendations of the Declaration of Helsinki as revised in Fortaleza (2013) for investigations with human subjects. Patients were thoroughly informed about the protocol, the treatment and its alternatives, the benefits and the possible risks and signed a written informed consent for the participation in the study. The study was approved by the relevant Ethical Committee (Comitato Etico Regione Calabria, Sezione Area Nord, Cosenza, Italy).

This superiority trial tested the null hypothesis of no difference in intraoperative complications and surgical time between 2 techniques for the lateral anrostomy during sinus floor elevation procedures (manual bone scraper [test] versus piezosurgery [control]), against the alternative hypothesis of a difference.

**Study Population**

Any healthy patient ( $\leq$ ASA 2) with an age  $>18$  years, with indications for a bilateral sinus floor augmentation to allow dental implants placement (crestal height  $<5$  mm) was eligible to enter the study. Exclusion criteria were the following: acute myocardial infarction within the past 2 months; uncontrolled coagulation disorders; uncontrolled diabetes (HBA1c  $>7.5\%$ ); radiotherapy to the head/neck district within the past 24 months; immunocompromised patient (HIV infection or chemotherapy within the past 5 years); present or past treatment with intravenous bisphosphonates; psychological or psychiatric problems; alcohol or drugs abuse; presence of uncontrolled or untreated periodontal disease; allergy to bovine collagen; presence of sinusal pathologies contraindicating sinus floor elevation procedures.

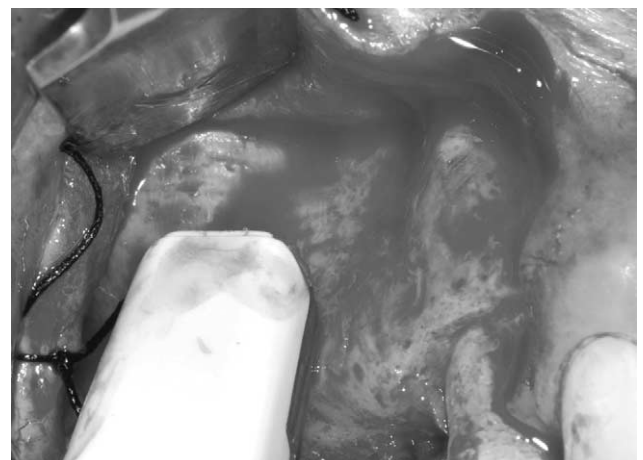**Surgical Procedure**

After performing local anesthesia (Artin 4%, Omnia, Italy—articaine 4% with epinephrine 1:100,000) and raising a full-thickness flap, an independent assessor opened the randomization sealed

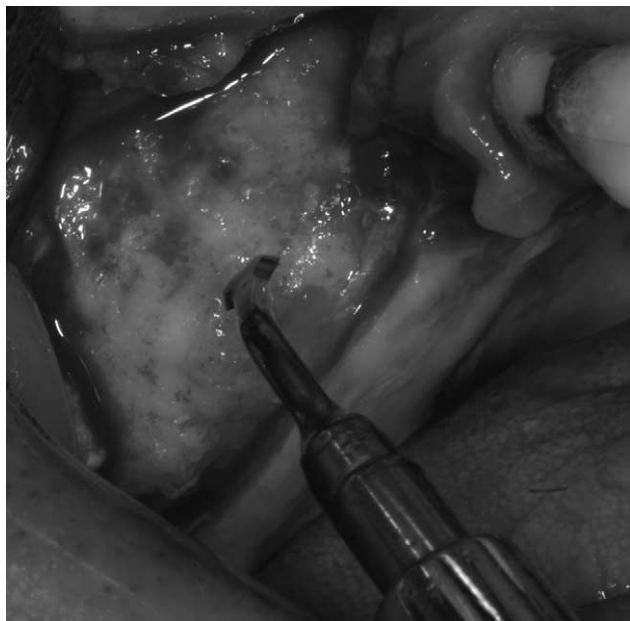opaque envelope, and the assigned treatment was revealed to the surgeon. Lateral anrostomy was performed by eroding the cortical wall until the membrane appeared evident under a thin bone layer, before outlining the window with ultrasonic instruments (OT1, Piezosurgery, Mectron, Italy): cortical wall reduction was performed by using a disposable bone scraper (Safescraper, Meta, Italy) on the test site and an ultrasonic insert (OP3, Piezosurgery, Mectron, Italy) on the control site (Figs. 1–4). Schneiderian membrane integrity was checked with Valsalva maneuver before starting its elevation, and then it was carefully detached from bone walls using ultrasonic instrumentation (EL1, Piezosurgery, Mectron, Italy) and manual curettes. After elevation, membrane integrity was assessed again with Valsalva maneuver before inserting the biomaterial. After the completion of the grafting procedure (Fisiograft Bone, Ghimas, Italy), the anrostomy was covered with a resorbable collagen membrane (BioGide, Geistlich, Switzerland) and flaps were sutured with Sentineri technique<sup>13</sup> and single stitches by using a synthetic monofilament (PTFE, Omnia, Italy).

Surgical time of the anrostomy (from the beginning of the erosion of the lateral wall to the moment in which the operator started to elevate the membrane) and any intra-surgical complication or adverse event were recorded.

The contralateral sinus floor augmentation was performed in the same surgical session following the same procedure, but performing



**FIGURE 3.** The action of the bone scraper performed on the cortical bone until the membrane is visible (test side).



**FIGURE 4.** Ultrasonic erosion of the lateral wall of the sinus (control side).

the cortical wall erosion with the technique not used in the first intervention.

Patients were prescribed with antibiotics for 6 days (amoxicillin 1 g twice a day or, in allergic patients, clarithromycin 250 mg twice a day) and NSAID (ibuprofen 600 mg), when needed.

## Outcome

This study evaluated the following outcome measures:

1. Any intraoperative complication defined as unexpected deviations from the normal treatment outcome (eg, membrane perforation, hemorrhagic events, residual alveolar crest fractures, etc.).
2. Surgical time for the antrostomy, expressed in minutes, and recorded from the beginning of the erosion of the lateral wall to the moment in which the operator started to elevate the membrane.

## Sample Size and Randomization

A web-based software (<http://www.dssresearch.com>) was used for the calculation of the sample size of this study. The calculation was performed assuming data present in the literature as expected percentage of membrane perforation in the 2 groups (control group, 11%; test group, 1%).<sup>8,12</sup> Based on these data, a sample of 22 patients (44 interventions—22 test, 22 control) should be included to reach 80% of statistical power (at  $\alpha = 0.05$  and  $\beta = 0.60$ ).

An investigator (PC), not involved in the selection and treatment of patients, prepared a computer-generated table using a balanced, randomly permuted block approach ([www.randomization.com](http://www.randomization.com)), and distributing all the patients into 2 groups (test and control). Patients assigned to the test group had the first intervention conducted with bone scrapers and the second with piezoelectric surgery, patients assigned to the control group had the opposite. Randomization codes were enclosed in numbered, identical, sealed, opaque envelopes. Envelopes were opened after the flap reflection: treatment allocation was concealed to the 2 operators in charge of enrolling and treating the patients of this trial.

## Statistical Analysis

Shapiro–Wilk test was applied to assess data normality, then a 2-sided Wilcoxon–Mann–Whitney test and, for analysis of time, a linear regression analysis was used (SPSS 18, SPSS Inc, Chicago, IL). All patients were included for analysis. The level of significance was set at  $\alpha = 0.05$ .

## RESULTS

Twenty-five patients (age  $58.2 \pm 11.4$  years, range 39–75 years, 10 females, 15 males) underwent bilateral sinus augmentation with lateral approach (Figs. 1–4). Thirty-two sinuses were classified as class V and 18 as class VI according to Cawood and Howell classification.<sup>14</sup> Twelve patients were no smokers, 2 were light smokers, and 9 were heavy smokers. No dropouts were registered in this study. One perforation of the Schneiderian membrane was observed both in test and in control group after the antrostomy (4.3%). Moreover, 3 perforations occurred in the test group (13%) and 2 in the control group (8.7%) during membrane elevation with manual instruments (total: 4 perforations in test group [16%]; 3 perforations in control group [12%]). The perforations were sealed with A-PRF membranes and surgical procedures were completed in all of the cases. Six of 7 perforations were associated with the presence of Underwood septa ( $P < 0.05$ ), which were encountered in 16 cases (32% prevalence; 9 in test group [36%], 7 in control group [28%]). Five perforations occurred in heavy smokers, 2 in no smoker patients. Vascular branches were encountered during antrostomy area in 9 cases (18% prevalence; 5 in test group [20%], 4 in control group [16%]). One minor hemorrhagic event occurred in test group during the antrostomy with the bone scraper: bleeding was easily controlled with the application of bone wax and procedure was completed. No other complications were registered during the surgical procedures.

Mean surgical time of the antrostomy in the test group was  $9'18'' (\pm 5'53'')$ , while in the control group was  $9'47'' (\pm 5'22'')$  (NS). Mean thickness of the lateral wall was 2.4 mm ( $\pm 2$  mm) in the test group and 2.6 mm ( $\pm 1.6$  mm) in the control group (NS).

Complete data are listed in Table 1.

## DISCUSSION

Sinus floor augmentation with lateral approach is considered a predictable procedure to regenerate an adequate bone volume for the placement of dental implants in posterior maxillary atrophic ridges. The traditional surgical technique, performed with rotary instruments, is associated with a substantially high risk of Schneiderian membrane perforation, which is the most common intraoperative complication. Perforation can occur either during the antrostomy or while separating and elevating the sinus membrane: in the attempt of reducing this adverse event, the use of ultrasonic devices during antrostomy has been introduced.<sup>2,9,15</sup> A recent systematic review showed that ultrasonic approach to lateral sinus augmentation halves the incidence of membrane perforation when compared with rotary instruments. Furthermore, ultrasonic erosion of the lateral wall of the sinus seems to be the most predictable technique in preventing from accidental perforations of Schneiderian membrane during sinus augmentation procedures.

Some authors proposed the use of manual bone scrapers for the erosion of the lateral wall, in order to harvest autogenous bone to be mixed with the grafting material: this technique seems promising, but it was not tested yet in comparative studies versus the ultrasonic erosion.<sup>11,12</sup> The results of the present investigation showed that the 2 procedures, even if characterized by different approaches, have the same clinical performances in terms of surgical time and intraoperative complications rate.

The integrity of the sinus membrane after elevation is a crucial factor for the success of the entire procedure. It is necessary to

TABLE 1. XXXXX

PT	Sex (M/F)	Age (y)	Smoke	TEST THK (mm)	CTRL THK (mm)	Test Time (s)	CRTL Time (s)	TEST PERF (Y/N)	CTRL PERF (Y/N)
1	M	63	NS	1	1	550	530	N	N
2	F	74	NS	0.5	1.5	326	438	N	N
3	M	64	NS	2.5	2.5	724	734	N	N
4	M	57	NS	1	3	329	622	N	N
5	M	46	LS	5	5	1050	1030	N	N
6	F	68	NS	1	1	375	372	N	N
7	M	46	HS	1	2	301	431	N	N
8	F	64	HS	1.5	2	363	313	N	N
9	F	39	HS	2	3.5	431	501	N	Y
10	F	68	NS	1	1	362	355	N	N
11	F	65	HS	2.5	2.5	528	427	N	N
12	M	41	LS	3.5	4	947	1021	N	N
13	M	46	HS	3	4	511	731	N	N
14	F	67	HS	3	0.5	1163	223	N	N
15	M	75	NS	0.5	1	901	1027	N	N
16	M	68	NS	2	1.5	1141	777	N	N
17	M	59	NS	0.5	1	551	780	N	N
18	F	45	NS	5.5	6	900	1380	N	N
19	F	57	HS	8	5	1200	600	N	N
20	M	41	HS	6	5	600	600	Y	N
21	M	58	HS	3	1.5	120	240	N	N
22	M	66	NS	1	2.5	180	240	N	N
23	F	75	NS	1.5	1.5	150	180	N	N
24	M	54	NS	1	2.5	120	300	N	N
25	F	46	LS	1.5	1.5	500	290	N	N
Total	11F; 14M	58.1 ± 11.4	13NS; 3LS; 9HS	2.4 ± 1.9	2.5 ± 1.5	572.9 ± 339.6	565.7 ± 308.2	1/25	1/25

HS, heavy smoker (>10 cigarettes/d); LS, light smoker (<10 cigarettes/d); NS, no smoker.

TEST THK: lateral wall thickness in the test site; CTRL THK: lateral wall thickness in the control site.

TEST PERF: perforation during antrostomy in the test site; CTRL PERF: perforation during antrostomy in the control site.

stabilize the graft during the healing period, avoiding the dispersion of the granules into the sinus cavity and constituting an important barrier helping to maintain sinus homeostasis. The presence of Underwood septa represents one of the possible risk factors for membrane perforation, even after an accurate presurgical planning.

It is clearly documented how the erosion of the lateral wall, both with scrapers and ultrasonic devices, makes the septa presence and localization evident to the surgeon, simplifying their management during the antrostomy.<sup>10,16–19</sup> However, septa remains a risk factor for perforation also after the antrostomy. In this study, 5 perforations (on a total of 7) occurred during membrane elevation with manual curettes, and all of them were associated with the presence of Underwood septa.

Lateral wall erosion seems also an advantage in identifying the course of vascular branches in the antrostomy area, contributing to minimizing the occurrence of hemorrhagic complications. An accurate presurgical planning is mandatory to avoid vascular lesions when using rotary instruments, while the contact of a working piezoelectric insert with a vessel is usually tolerated without problems.<sup>4,10,20,21</sup> Attention should also be paid when using manual bone scrapers in proximity with large vessels: in this trial we recorded a case of bleeding during the lateral wall erosion with this instrument, which was easily controlled with the application of bone wax.

Bone harvested from the lateral wall is usually mixed with the biomaterial selected for sinus grafting: the harvesting technique could possibly affect the collected bone qualities (Figs. 5 and 6). Some authors demonstrated that cells in bone samples harvested by bone scraper showed higher viability and a stronger paracrine

potential compared with bone particles collected with piezoelectric devices. Bone scraper harvesting seems to have a positive impact on gene expression favoring bone formation when compared with piezosurgery: changes in gene expression could be a cellular


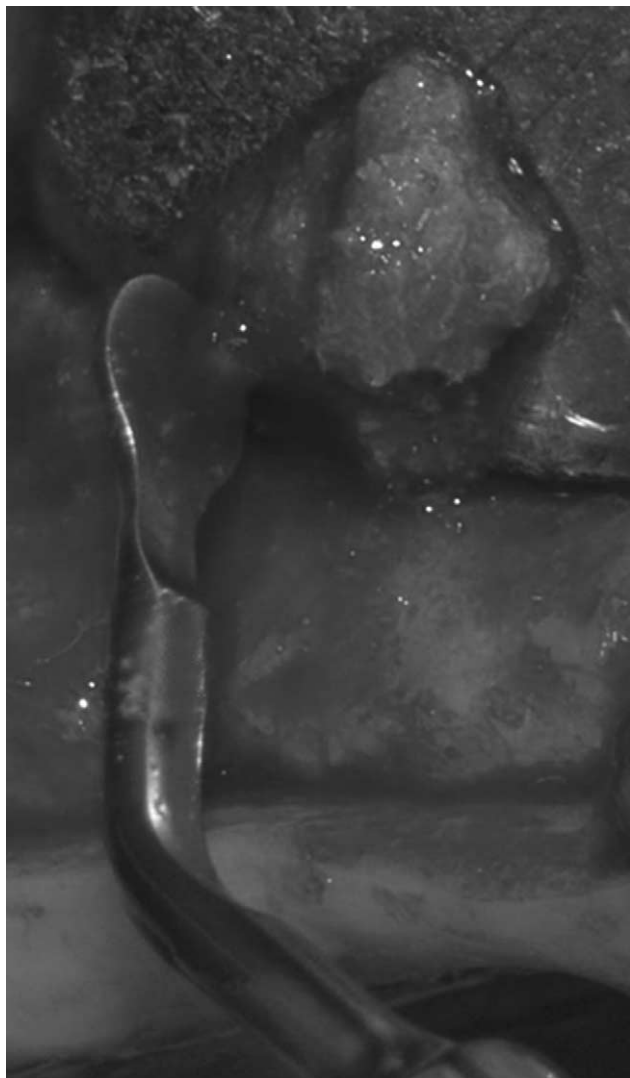


FIGURE 5. A detail of the quality of bone harvested by using a manual bone scraper.



**FIGURE 6.** A detail of the quality of bone harvested by using an ultrasonic device.

response to the biomechanical stress induced by the different harvesting techniques or a shift in the remaining cell population including osteoblast, lining cells, and osteocytes.<sup>22,23</sup> Another work showed that bone particles collected with a manual scraper had a smaller nonvital surface than particles harvested using a piezoelectric device.<sup>24</sup>

On the other hand, the physical and mechanical characteristics of the piezoelectric devices have several clinical advantages: precise and selective cutting, easy surgical control, and better visualization of the surgical field.<sup>25–27</sup> Moreover, their use in various fields of osseous surgery seems to improve the first phases of bone healing.<sup>28,29</sup> Several recent researches demonstrated that the bone treated with ultrasonic devices is rich in growth factors and there is a documented control on the modulation of the inflammatory process following piezoelectric bone surgery. Biomolecular researches demonstrated an early increase in the concentration of bone morphogenic protein (BMP-4), transforming growth factor  $\beta$ 2, tumor necrosis factor when comparing piezosurgery to rotary instruments and, at the same time, a lower production of interleukin-1 $\beta$ , heat shock protein 70, and pro-inflammatory cytokines.<sup>30–32</sup>

The area of maxillofacial surgical techniques reached effective and predictable results during the last years and management of complex interventions became easier, with a lower morbidity for the patients and decrease in complication rates. New minimally invasive techniques and the concomitant progress of the tissue engineering in the field of biomaterials led the surgery to be less traumatic, more controlled, and easier to be performed.<sup>33–36</sup> The modifications of the traditional approach to lateral sinus floor elevation that have been introduced to reduce intraoperative complications are part of this clinical and scientific development. Both devices tested in this randomized clinical trial showed good results and could be adopted in the clinical practice, guarantying increased intraoperative control and safety for a less risky surgery.

## REFERENCES

1. van den Bergh JP, ten Bruggenkate CM, Disch FJ, et al. Anatomical aspects of sinus floor elevations. *Clin Oral Implants Res* 2000;11:256–265
2. Zijdeveld SA, van den Bergh JP, Schulten EA, et al. Anatomical and surgical findings and complications in 100 consecutive maxillary sinus floor elevation procedures. *J Oral Maxillofac Surg* 2008;66:1426–1438
3. Rosano G, Taschieri S, Gaudy JF, et al. Maxillary sinus vascular anatomy and its relation to sinus lift surgery. *Clin Oral Implants Res* 2011;22:711–715
4. Maridati P, Stoffella E, Speroni S, et al. Alveolar antral artery isolation during sinus lift procedure with the double window technique. *Open Dent J* 2014;8:95–103
5. Güncü GN, Yildirim YD, Wang HL, et al. Location of posterior superior alveolar artery and evaluation of maxillary sinus anatomy with computerized tomography: a clinical study. *Clin Oral Implants Res* 2011;22:1164–1167
6. Tatum OH Jr. Maxillary and sinus implant reconstructions. *Dent Clin North Am* 1986;30:207–229
7. Boyne PJ, James RA. Grafting of the maxillary sinus floor with autogenous marrow and bone. *J Oral Surg* 1980;38:613–616
8. Stacchi C, Orsini G, Di Iorio D, et al. Clinical, histologic, and histomorphometric analyses of regenerated bone in maxillary sinus augmentation using fresh frozen human bone allografts. *J Periodontol* 2008;79:1789–1796
9. Wallace SS, Tarnow DP, Froum SJ, et al. Maxillary sinus elevation by lateral window approach: evolution of technology and technique. *J Evid Based Dent Pract* 2012;12:161–171
10. Stacchi C, Vercellotti T, Toschetti A, et al. Intraoperative complications during sinus floor elevation using two different ultrasonic approaches: a two-center, randomized, controlled clinical trial. *Clin Implant Dent Relat Res* 2015;17(suppl 1):e117–e125
11. Martos Díaz P, Naval Gías L, Sastre Pérez J, et al. Sinus elevation by in situ utilization of bone scrapers: technique and results. *Med Oral Patol Oral Cir Bucal* 2007;12:e537–e541
12. Galindo-Moreno P, Moreno-Riestra I, Avila G, et al. Histomorphometric comparison of maxillary pristine bone and composite bone graft biopsies obtained after sinus augmentation. *Clin Oral Implants Res* 2010;21:122–128
13. Sentineri R, Lombardi T, Berton F, et al. Laurell-Gottlow suture modified by Sentineri for tight closure of a wound with a single line of sutures. *Br J Oral Maxillofac Surg* 2016;54:e18–e19
14. Cawood JI, Howell RA. A classification of the edentulous jaws. *Int J Oral Maxillofac Surg* 1988;17:232–236
15. Vercellotti T, De Paoli S, Nevins M. The piezoelectric bony window osteotomy and sinus membrane elevation: introduction of a new technique for simplification of the sinus augmentation procedure. *Int J Periodontics Restorative Dent* 2001;21:561–567
16. Beretta M, Cicciù M, Bramanti E, et al. Schneider membrane elevation in presence of sinus septa: anatomic features and surgical management. *Int J Dent* 2012;2012:261905
17. Rancitelli D, Borgonovo AE, Cicciù M, et al. Maxillary sinus septa and anatomic correlation with the Schneiderian membrane. *J Craniofac Surg* 2015;26:1394–1398
18. Yılmaz HG, Tözüm TF. Are gingival phenotype, residual ridge height, and membrane thickness critical for the perforation of maxillary sinus? *J Periodontol* 2012;83:420–425

19. Schwarz L, Schiebel V, Hof M, et al. Risk factors of membrane perforation and postoperative complications in sinus floor elevation surgery: review of 407 augmentation procedures. *J Oral Maxillofac Surg* 2015;73:1275–1282
20. Testori T, Rosano G, Taschieri S, et al. Ligation of an unusually large vessel during maxillary sinus floor augmentation. A case report. *Eur J Oral Implantol* 2010;3:255–258
21. Velasco-Torres M, Padiál-Molina M, Alarcón JA, et al. Maxillary sinus dimensions with respect to the posterior superior alveolar artery decrease with tooth loss. *Implant Dent* 2016;25:464–470
22. Robling AG, Turner CH. Mechanical signaling for bone modeling and remodeling. *Crit Rev Eukaryot Gene Expr* 2009;19:319–338
23. Miron RJ, Gruber R, Hedbom E, et al. Impact of bone harvesting techniques on cell viability and the release of growth factors of autografts. *Clin Implant Dent Relat Res* 2013;15:481–489
24. Bacci C, Lucchiari N, Valente M, et al. Intra-oral bone harvesting: two methods compared using histological and histomorphometric assessments. *Clin Oral Implants Res* 2011;22:600–605
25. Stacchi C, Constantinides F, Biasotto M, et al. Relocation of a malpositioned maxillary implant with piezoelectric osteotomies: a case report. *Int J Periodontics Restorative Dent* 2008;28:489–495
26. Schaaeren S, Jaquière C, Heberer M, et al. Assessment of nerve damage using a novel ultrasonic device for bone cutting. *J Oral Maxillofac Surg* 2008;66:593–596
27. Stacchi C, Berton F, Turco G, et al. Micromorphometric analysis of bone blocks harvested with eight different ultrasonic and sonic devices for osseous surgery. *J Craniomaxillofac Surg* 2016;44:1143–1151
28. Vercellotti T, Nevins ML, Kim DM, et al. Osseous response following resective therapy with piezosurgery. *Int J Periodontics Restorative Dent* 2005;25:543–549
29. Stacchi C, Vercellotti T, Torelli L, et al. Changes in implant stability using different site preparation techniques: twist drills versus piezosurgery. A single-blinded, randomized, controlled clinical trial. *Clin Implant Dent Relat Res* 2013;15:188–197
30. Preti G, Martinasso G, Peirone B, et al. Cytokines and growth factors involved in the osseointegration of oral titanium implants positioned using piezoelectric bone surgery versus a drill technique: a pilot study in minipigs. *J Periodontol* 2007;78:716–722
31. Gülnahar Y, Hüseyin Köşger H, Tutar Y. A comparison of piezosurgery and conventional surgery by heat shock protein 70 expression. *Int J Oral Maxillofac Surg* 2013;42:508–510
32. Aimetti M, Ferrarotti F, Bergandi L, et al. Increase in periodontal interleukin-1 $\beta$  gene expression following osseous resective surgery using conventional rotary instruments compared with piezosurgery: a split-mouth randomized clinical trial. *Int J Periodontics Restorative Dent* 2016;36:489–496
33. Maiorana C, Beretta M, Rancitelli D, et al. Histological features and biocompatibility of bone and soft tissue substitutes in the atrophic alveolar ridge reconstruction. *Case Rep Dent* 2016;2016:3608602
34. Maiorana C, Beretta M, Grossi GB, et al. Histomorphometric evaluation of anorganic bovine bone coverage to reduce autogenous grafts resorption: preliminary results. *Open Dent J* 2011;5:71–78
35. Cicciù M, Herford AS, Stoffella E, et al. Protein-signaled guided bone regeneration using titanium mesh and Rh-BMP2 in oral surgery: a case report involving left mandibular reconstruction after tumor resection. *Open Dent J* 2012;6:51–55
36. Dursun CK, Dursun E, Eratalay K, et al. Effect of porous titanium granules on bone regeneration and primary stability in maxillary sinus: a human clinical, histomorphometric, and microcomputed tomography analyses. *J Craniofac Surg* 2016;27:391–397