

Sergio Spinato, Claudio Stacchi, Teresa Lombardi, Fabio Bernardello, Marcello Messina, Sergio Dovigo, Davide Zaffe

Influence of abutment height and vertical mucosal thickness on early marginal bone loss around implants: A randomised clinical trial with an 18-month post-loading clinical and radiographic evaluation

KEY WORDS

abutment height, marginal bone loss, platform switching, vertical mucosal thickness

ABSTRACT

Purpose: To investigate the influence of vertical mucosal thickness on marginal bone loss around implants with short and long prosthetic abutments and the marginal bone loss progression rate up to 18 months after prosthetic loading.

Materials and methods: Internal hex platform-switched implants were placed equicrestally using a two-stage protocol in the posterior mandible of two groups of patients with different vertical mucosal thickness, thin (≤ 2.0 mm) and thick (> 2.0 mm). Elevated prosthetic abutments of different heights (1 mm or 3 mm) were randomly assigned for single screw-retained crowns in both groups. Mesial and distal marginal bone loss were measured at implant placement (T0) and crown delivery (after 4 months [T1]), and after 6 (T2), 12 (T3) and 18 months (T4) of functional loading.

Results: Eighty implants were placed in eighty patients. Three patients dropped out at T2. At T4, 74 out of 77 implants were functioning, resulting in a 96% survival rate. Marginal bone loss (mean \pm SE) at T2 was significantly greater in the 1-mm abutment groups (0.61 ± 0.09 mm with thin mucosa; 0.64 ± 0.07 mm with thick mucosa) than in the 3-mm abutment groups (0.32 ± 0.07 mm with thin mucosa; 0.26 ± 0.04 mm with thick mucosa). The marginal bone loss pattern over 18 months of loading showed that the greatest amount of marginal bone loss occurred during the first 6 months of function.

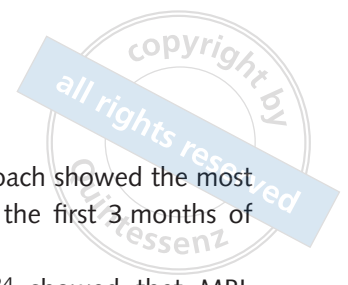Conclusions: Internal hex platform-switched implants placed equicrestally and restored with 1-mm abutments presented greater marginal bone loss than identical implants with 3-mm abutments, with vertical mucosal thickness having no significant influence.

Conflict-of-interest statement: *The authors have no direct or indirect financial interest in the products listed or information presented in this article.*

Introduction

Early marginal bone loss (MBL) is a common and non-progressive phenomenon first described by Adell et al¹. In the late 1980s and during the 1990s

it was accepted that less than 2 mm of MBL can be expected in the first year after implant placement and that an average of 0.1 to 0.2 mm of MBL may occur thereafter. It was also accepted that after the first year, bone levels would remain remarkably



stable for years^{1,2}. For this reason, the amount of bone loss around implant necks has long been used as a criterion for defining long-term implant success². However, a multifactorial aetiology has been postulated for MBL, even though the biological mechanisms have not yet been completely understood³⁻⁵.

Factors influencing early MBL include surgical trauma, presence of an implant–abutment microgap, supracrestal tissue height⁶ and implant neck characteristics. During the submerged healing period, an initial marginal bone remodelling process of variable entity may occur as a consequence of surgical trauma (i.e. excessive insertion torque and/or bone overheating)^{3,4,7,8}.

The implant–abutment interface position at bone crest level or below may determine greater peri-implant bone remodelling due to bacterial colonisation of the microgap^{9,10}. The platform-switching concept is based upon the use of a narrower abutment and the resulting mismatch with the implant neck diameter¹¹. This determines a significant reduction of bone resorption as a consequence of an increased distance between the bone crest and the area of inflammation produced by bacterial toxins in the implant–abutment microgap¹⁰.

Other factors related to implant neck design, such as use of microthreads and modifications to implant surface characteristics, can influence peri-implant bone loss^{12,13}.

Moreover, supracrestal tissue height establishment around implants has been shown to elicit peri-implant bone remodelling following abutment connection^{14,15}. It has recently been demonstrated¹⁶⁻²² that less peri-implant MBL occurs if an elevated prosthetic abutment is used to allow supracrestal tissue height establishment around implants surrounded by both thin and thick mucosa, irrespective of vertical mucosal thickness²³.

The pattern of peri-implant MBL over time has been widely discussed in the literature. The major component of early MBL around implants placed in a two-stage approach seems to occur after abutment connection, increasing significantly up to 6 months after prosthetic loading before stabilising^{23,24}. On the other hand, MBL around implants

placed in a one-stage approach showed the most significant changes within the first 3 months of healing before loading^{25,26}.

Galindo-Moreno et al²⁴ showed that MBL greater than 0.44 mm after 6 months of loading reveals the likelihood of a loss of more than 2 mm at the 18-month follow-up. These findings are in agreement with a recent prospective study²⁷ which demonstrated that the variation in MBL in the first month significantly influenced 12-month MBL values and is a predictor for bone alterations occurring after 1 year of treatment.

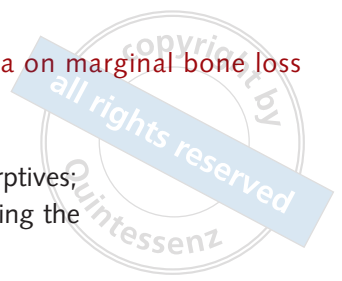The aim of this prospective study was to analyse MBL progression rates at four different time points (4 months after implant placement and 6, 12 and 18 months after implant loading) and to investigate the influence of peri-implant vertical mucosal thickness on MBL around internal hex platform-switched implants when using either short or long abutments for prosthetic restoration.

Materials and methods

Experimental design

This multicentre randomised controlled trial was reported following the Consolidated Standards of Reporting Trials (CONSORT) guidelines (<http://www.consort-statement.org>). All procedures were in full accordance with the principles outlined in the Good Clinical Practice Directive (Directive 2005/28/EC) stating that all ethical principles of the 2008 WMA Helsinki Declaration²⁸ must be adhered to in clinical research involving human subjects. The study protocol was approved by the relevant Ethical Committee (Regione Calabria, Sezione Area Nord, No. 67/2016), and was recorded on a public register of clinical trials (www.clinicaltrials.gov, NCT03229005).

The clinical data were collected and evaluated by trained and experienced examiners (CS, SS, FB, TL, DZ), who participated in a calibration meeting prior to the start of the study, in order to standardise assessment of study variables and data acquisition. The data were recorded on a specific case report form.



All patients signed an informed consent form in which all procedures of the study were detailed, and consented to use of their personal data for research purposes.

Patient selection

This randomised prospective study is based on data from a set of patients, some of whom were included in a previously published 12-month clinical trial²³.

All patients were selected consecutively from a pool and treated in two private practices by two experienced surgeons (CS and SS). The patients were partially edentulous and required placement of at least one single implant in the pristine bone in the posterior mandible. In the case of multiple implants, only the most mesial implant was evaluated such that each patient provided only one implant. All single-unit prosthetic crowns were delivered.

The local inclusion criteria were as follows:

- presence of keratinised mucosa with a minimum buccolingual width of 3 mm;
- bone crest with at least 6 mm of width and 9 mm of height above the mandibular canal, without concomitant or previous bone augmentation procedures;
- presence of opposing dentition.

The additional inclusion criteria were as follows:

- age > 18 years;
- good general health;
- non-smoker;
- absence of disease affecting bone metabolism and wound healing;
- no regular medication consumption for at least 3 months prior to treatment.

The exclusion criteria were as follows:

- untreated periodontitis;
- poor oral hygiene and motivation (full mouth plaque score [FMPS] > 25%);
- lack of implant primary stability;
- active infection;
- uncontrolled diabetes (glycated haemoglobin \geq 8%);
- history of head or neck radiation therapy;

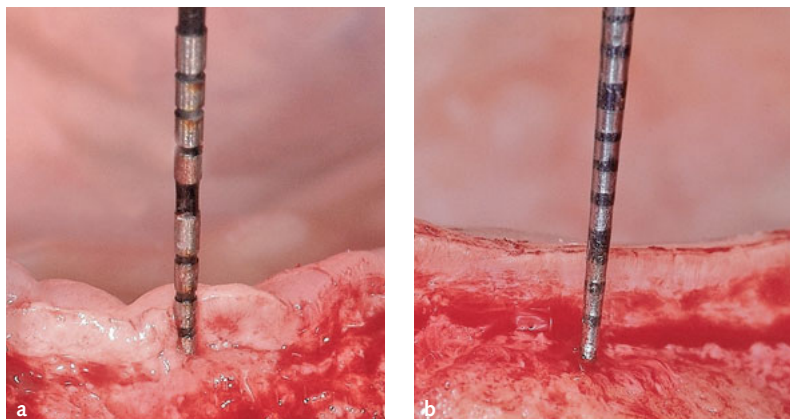
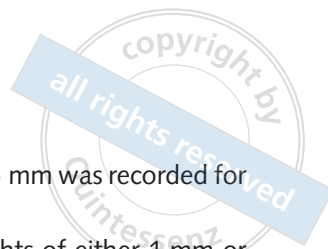- present or past treatment with antiresorptives;
- pregnancy or lactation at any time during the study.

Before implant placement, all patients received oral hygiene instruction and were treated with non-surgical periodontal therapy where necessary. Prior to surgery, CBCT was performed to evaluate crestal bone dimensions.

Surgical and restorative procedures

All patients were treated according to the following protocol. After administration of 4% articaine solution with adrenaline 1:100,000 (Artin, Omnia, Fidenza, Italy), a mid-crestal incision was made in the centre of the edentulous bone crest. A full-thickness flap was elevated in two phases as described elsewhere²⁹: after buccal flap elevation, a periodontal probe (15 mm, PCP-UNC15; Hu-Friedy, Chicago, IL, USA) was used in the centre of the future implant site to measure the mucosal thickness of the unseparated lingual flap, then the lingual flap was opened, exposing the alveolar crest. The implant location was subsequently marked with a small-diameter pilot drill using a prefabricated surgical guide.

A two-stage protocol was adopted according to the manufacturer's recommendations. When necessary, a piezoelectric tip (OP3, Piezosurgery Touch, Mectron, Carasco, Italy) was utilised to level the bone crest before implant site preparation for ideal equicrestal implant placement. The site was prepared to permit insertion of 1-mm machined-collar internal hex platform-switched implants (Shape1BC, I-RES, Lugano, Switzerland) at crestal level. Owing to crest width, all implants were 3.75 mm in diameter and operators selected appropriate implant lengths (8, 10, 11.5 mm) according to available bone crest height. All implants were submerged and flaps were sutured. Patients were prescribed with antibiotics (amoxicillin 1 g twice a day) for 6 days, and nonsteroidal anti-inflammatory drugs (ibuprofen 600 mg) when needed. Sutures were removed 12 to 14 days after surgery. Patients were instructed not to utilise removable prostheses during the healing period.



Figs 1a-b Images showing the vertical mucosal thickness measurement at implant placement of a patient in (a) group A (thin mucosa, ≤ 2.0 mm) and (b) group B (thick mucosa, > 2.0 mm).

Stage-two surgery was carried out after 3 months of submerged healing. A mid-crestal incision was performed and measurement of vertical mucosal thickness was repeated with the previously described modalities. A 3-mm height healing abutment was used in all implants.

Final impressions were taken 3 weeks after stage-two surgery. The prosthetic framework was bonded to a prefabricated titanium abutment (of either 1 or 3 mm, randomly assigned) and, after functional and aesthetic try-in, a single-unit screw-retained metal ceramic crown was delivered.

The fixation screw was torqued to 30 Ncm following the manufacturer's guidelines. Screw access was then closed using light-cured composite resin.

Patients received individual oral hygiene instructions and were recalled every 6 months (or less, if necessary) to ensure that periodontal health was maintained throughout the entire study period.

Treatment allocation

Based upon vertical mucosal thickness measured at implant placement (Fig 1) and confirmed at stage-two surgery, patients were first clustered in two groups: group A, the thin mucosa group (≤ 2.0 mm), and group B, the thick mucosa group (> 2.0 mm)³⁰. Vertical mucosal thickness was measured at stage-one and stage-two surgery by the same experienced operator who placed the implant (CS or SS). The mean of three measurements

performed to the nearest 0.5 mm was recorded for each surgical site.

To assign abutment heights of either 1 mm or 3 mm for each implant, patients were allocated using two randomisation lists generated by a randomisation plan generator (www.randomization.com), one for group A (thin mucosa) and one for group B (thick mucosa).

Patients' assignment to the different groups was enclosed in identical, opaque, sealed envelopes which were opened after the final impression had been taken, revealing which treatment was to be performed to the clinician. Therefore, treatment allocation was concealed from the investigators responsible for enrolling and treating the patients.

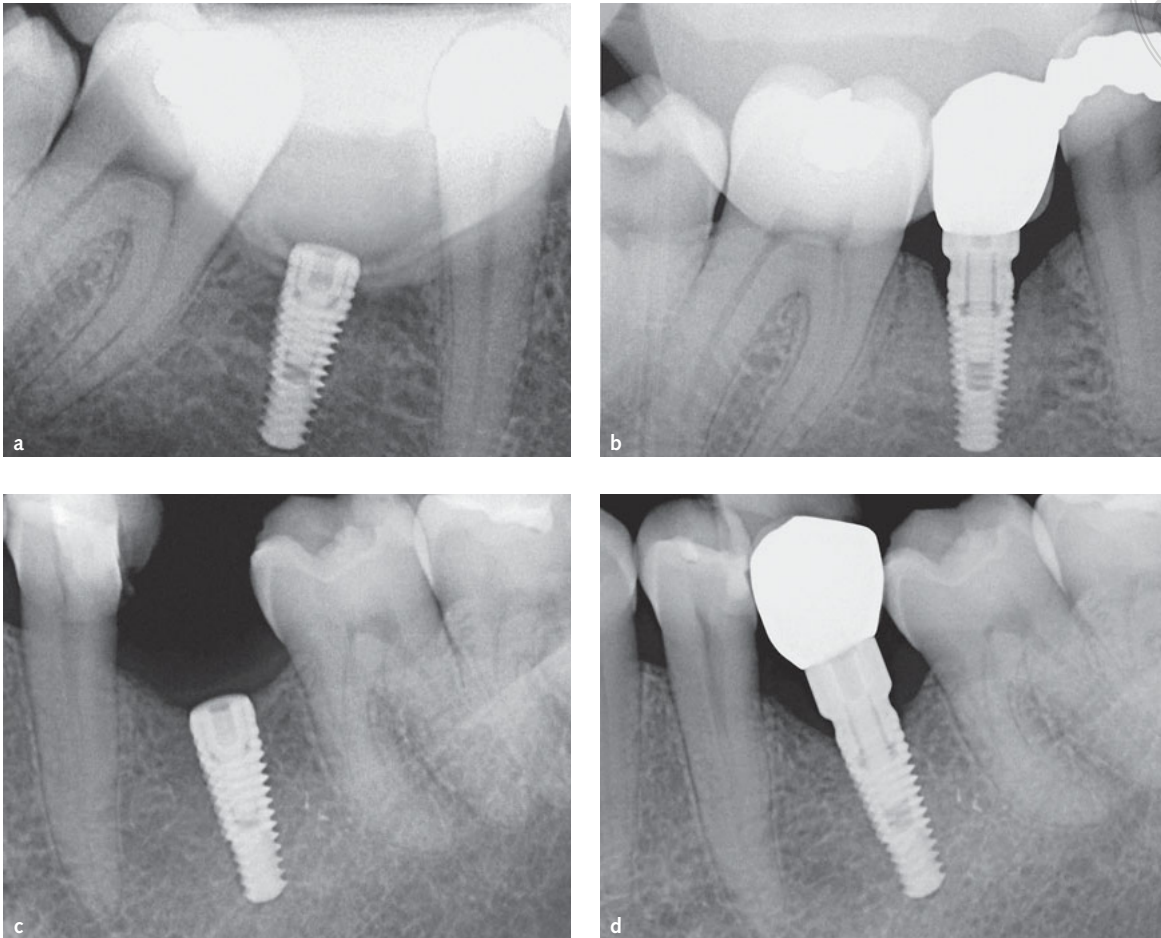
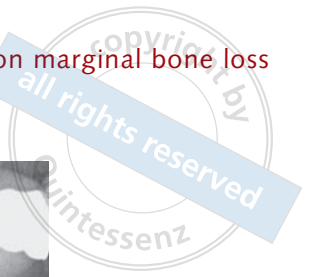Radiographic measurements

Digital radiographs, customised for each patient with a bite jig, were taken using a long cone paralleling technique with a Rinn-type film holder at the time of implant placement (baseline), at prosthetic crown delivery (4 months after implant placement), and after 6, 12 and 18 months of prosthetic loading. All radiographs were performed using the same x-ray generator technology (FOCUS, KaVo, Biberach, Germany), set with the same parameters (60 kV, 7 mA).

Marginal bone level was calculated on each radiograph as the linear measurement of the distance between two points, the most coronal point of the implant platform and the most coronal bone-to-implant contact, corrected referring to the known height and diameter of each implant (Fig 2). The vertical distance between the most coronal point of the implant platform and the most coronal bone-to-implant contact was measured on the mesial and distal aspects of the implant at:

- T0, implant placement;
- T1, prosthesis delivery (4 months after T0);
- T2, 6 months of prosthetic loading;
- T3, 12 months of prosthetic loading;
- T4, 18 months of prosthetic loading.

Mesial (mMBL) and distal (dMBL) MBL were calculated as bone changes between T0, T1, T2, T3 and T4. Therefore, an increase in vertical distance



Figs 2a-d Radiographs at baseline (**a and c**) and 18 months after prosthetic loading (22 months after implant placement) (**b and d**), showing implants with short (1-mm) (**a and b**) and long (3-mm) abutments (**c and d**). (Note the bite jig in the upper part of each image.)

between the implant platform reference point and the crestal bone (the most coronal bone-to-implant contact) was considered indicative of bone loss, whilst a decrease in distance was considered indicative of bone gain.

The bone loss pattern during the four periods (T0–T1; T1–T2; T2–T3; T3–T4) was evaluated by calculating the monthly differential MBL (mdMBL) using the equation $mdMBL_x = (MBL_x - MBL_{x-1}) / (x - x - 1)$ [MBL at time x minus MBL at time $x-1$, divided by months elapsed between time x and time $x-1$, with $4 \text{ months} \leq x \leq 22 \text{ months}$].

Radiographs demonstrating any deformation, darkness and/or other problem were immediately repeated. All radiographic measurements were made by a single calibrated examiner blinded to mucosal thickness (FB), using a 30-inch LED-backlit

colour diagnostic display with Kodak Dental Imaging Software (Kodak, Eastman Kodak, Rochester, NY, USA). Each measurement was repeated three times at three different time points, as proposed by Gomez-Roman and Launer³¹. Examiner calibration was performed by assessing ten radiographs, with a different author (TL) serving as reference examiner. Intra-examiner and inter-examiner concordances were 96.1% and 90.4%, respectively, for linear measurements within $\pm 0.1 \text{ mm}$.

Statistical analysis

Based upon data published in previous studies^{16,30}, the sample size of this study was computed using Primer of Biostatistics (6th ed) software³². Considering two group comparisons, a sample of 12



Table 1 Position (according to FDI notation) and length of 3.75-mm diameter implants placed in the 74 patients involved in the study

Implant length (mm)	No. of implants	Position					
		34	35	36	44	45	46
8	14	1	2	1	4	3	3
10	53	5	5	16	8	2	17
11.5	7	0	0	3	1	2	1

patients for each treatment group was required to detect significant differences (confidence level 5% with statistical power of 80%), with an expected difference in MBL of 0.3 mm (± 0.25 mm).

Statistical analysis of radiographic measurements was performed using Primer of Biostatistics (6th ed) software³². The patient was considered the statistical unit (one implant per patient). Intra- and intergroup comparisons were carried out using the one-way analysis of variance (ANOVA) test.

Differences in patient age, gender, MBL and mdMBL in ANOVA comparisons were considered marginally significant for $P \leq 0.1$, significant for $P \leq 0.05$ and highly significant for $P \leq 0.01$.

Results

A total of 80 consecutive selected patients were enrolled and treated in two clinical centres. In all 80 patients, vertical mucosal thickness was measured at stage-one surgery and rechecked at stage-two surgery (37 patients with thin mucosa, group A; 43 patients with thick mucosa, group B).

At T2, three patients dropped out (one patient died and two patients moved abroad). Two implants failed to osseointegrate at T1 and another implant failed due to peri-implantitis after 16 months of loading, thus 74 implants were functioning satisfactorily at T4 (Table 1), resulting in a 96.1% implant survival rate. Seventy-four patients (36 male, 38 female, mean age \pm standard deviation 51.1 ± 1.38 years, range 26 to 70) were included in the final analysis. No significant differences were demonstrated among the four subgroups for age or gender ($P > 0.05$) after ANOVA.

Primary wound closure was achieved in all surgeries and no complications or adverse effects

were recorded during follow-up. All 74 implants, 3.75 mm in diameter, placed in 74 patients (Table 1) functioned satisfactorily at T2, T3 and T4.

At stage-one surgery, the vertical mucosal thickness (mean \pm SE) was ≤ 2 mm in 32 patients (1.58 ± 0.06 mm, group A) and > 2 mm in 42 patients (3.74 ± 0.15 mm, group B). At stage-two surgery, the vertical mucosal thickness was 1.48 ± 0.07 mm in group A and 3.46 ± 0.15 mm in group B. The differences in vertical mucosal thickness between the first and the second measurement were not statistically significant (group A, $P = 0.309$; group B, $P = 0.201$).

Of the 74 patients, 38 (subgroup 1) received a 1-mm abutment and 36 (subgroup 3) received a 3-mm abutment. In subgroup 1, 16 patients (group A1) had thin mucosa (1.53 ± 0.10 mm) whereas 22 (group B1) had thick mucosa (3.70 ± 0.20 mm). In subgroup 3, 16 patients (group A3) had thin mucosa (1.63 ± 0.08 mm) and 20 (group B3) had thick mucosa (3.78 ± 0.22 mm).

Radiographic measurements

In one-third of patients, a very small MBL was detected before prosthesis delivery (T0–T1), but mean MBL did not differ among the four groups. Intragroup comparisons showed that the greatest amount of MBL occurred between T1 and T2 in all four groups, reaching statistical significance. At the following observation periods (T2–T3 and T3–T4), average MBL values tended to stabilise in all four groups, showing a minimal increase without statistical significance when compared to T2 (Fig 3).

Intergroup comparisons highlighted that at T2, the average MBL in the short abutment groups (0.61 ± 0.09 mm with thin mucosa; 0.64 ± 0.07 mm with thick mucosa) was

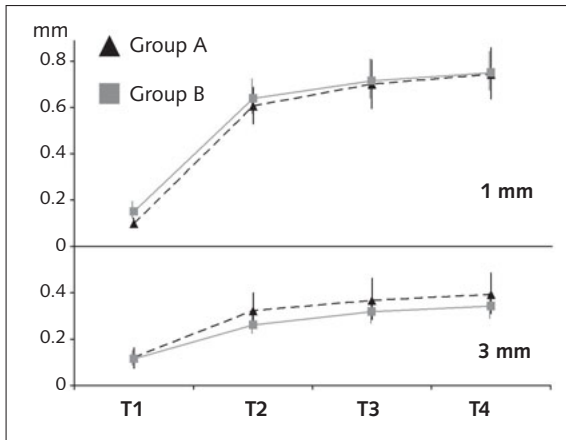


Fig 3 MBL, expressed in mm (mean \pm SE), in group A (thin mucosa, ≤ 2.0 mm) and group B (thick mucosa, > 2.0 mm) with 1-mm and 3-mm abutments, at the four evaluation time points. Note how MBL increased from T1 to T4 in all four groups, but to a greater extent in A1/B1 than in A3/B3. Also note how, particularly with the 3-mm abutments, MBL was slightly greater in group A. (T1, 4 months from implant placement; T2, after 6 months of functional loading; T3, after 12 months of functional loading; T4, after 18 months of functional loading.)

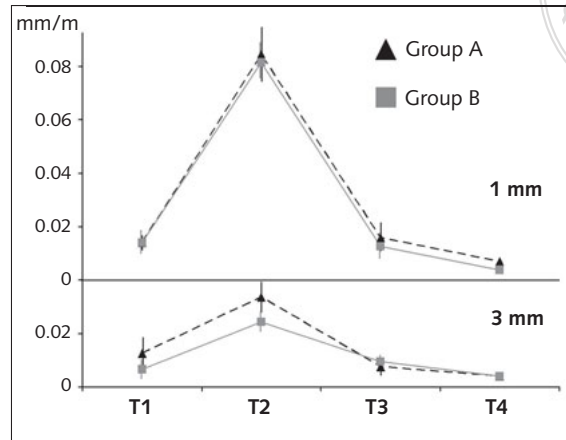


Fig 4 mdMBL, expressed in mm/month (mean \pm SE), in group A (thin mucosa, ≤ 2.0 mm) and group B (thick mucosa, > 2.0 mm), with 1-mm and 3-mm abutments, at the four evaluation time points. Note how mdMBL increased from T1 to T2, and subsequently reduced greatly up to T4 in all four groups, but with greater values in A1/B1. Also note how, particularly at T1 and T2 for the 3-mm abutments, mdMBL was greater in group A.

Table 2 MBL, expressed in mm, in group A (thin mucosa, ≤ 2.0 mm) and group B (thick mucosa, > 2.0 mm) with 1-mm and 3-mm abutments, at the four evaluation time points

Group	No. of implants	T1 MBL	P	T2 MBL	P	T3 MBL	P	T4 MBL
A1	16	0.10 \pm 0.03	< 0.01	0.61 \pm 0.09	0.60	0.70 \pm 0.11	0.72	0.74 \pm 0.12
A3	16	0.12 \pm 0.04	< 0.05	0.32 \pm 0.07	0.66	0.37 \pm 0.08	0.83	0.39 \pm 0.08
B1	22	0.15 \pm 0.03	< 0.01	0.64 \pm 0.07	0.52	0.71 \pm 0.09	0.76	0.75 \pm 0.09
B3	20	0.12 \pm 0.03	< 0.01	0.26 \pm 0.04	0.36	0.32 \pm 0.05	0.72	0.34 \pm 0.05

T1, prosthesis delivery; T2, 6 months of loading; T3, 12 months of loading; T4, 18 months of loading.

Values, mean \pm standard error; P, probability after ANOVA test.

significantly greater than in the long abutment groups (0.32 \pm 0.07 mm with thin mucosa; 0.26 \pm 0.04 mm with thick mucosa; Table 2). When using the same abutment height (1 or 3 mm), no significant differences were observed between the thin and thick mucosa groups at any time points. Complete data are listed in Table 2.

The analysis of monthly differential MBL (mdMBL) confirmed this pattern. mdMBL increased from T1 to T2, and subsequently reduced greatly up to T4 in all four groups (Fig 4). Similarly to MBL, intragroup comparisons showed that the average mdMBL was significantly greater in both short and long abutment groups during T1–T2 than in all the other time intervals. No significant

differences were observed between the mdMBL for the short (range 0.006 to 0.016 mm/month) and long (range 0.004 to 0.013 mm/month) abutment groups during T0–T1 and T3–T4. Intragroup comparisons showed that during T1–T2, the average mdMBL (Table 3) for both short abutment groups (0.084 mm/month with thin mucosa; 0.082 mm/month with thick mucosa) was significantly greater than the average mdMBL for the long abutment groups (0.034 mm/month with thin mucosa; 0.024 mm/month with thick mucosa). When using the same abutment height (1 or 3 mm), no significant differences were demonstrated between the thin and thick mucosa groups at any time point.

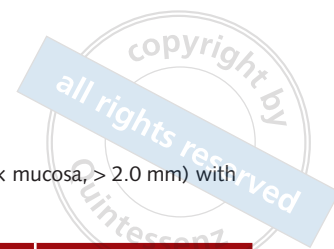

Table 3 mdMBL, expressed in mm/month, in group A (thin mucosa, ≤ 2.0 mm) and group B (thick mucosa, > 2.0 mm) with 1-mm and 3-mm abutments, at the four evaluation time points

Group	No. of implants	T1	T2	T3	T4
A1	16	0.014 \pm 0.003	0.084 \pm 0.011	0.016 \pm 0.005	0.007 \pm 0.0016
A3	16	0.013 \pm 0.006	0.034 \pm 0.006	0.008 \pm 0.002	0.004 \pm 0.0006
B1	22	0.014 \pm 0.004	0.082 \pm 0.008	0.013 \pm 0.005	0.006 \pm 0.0008
B3	20	0.007 \pm 0.004	0.024 \pm 0.004	0.009 \pm 0.002	0.004 \pm 0.0010

T1, prosthesis delivery; T2, 6 months of loading; T3, 12 months of loading; T4, 18 months of loading.

Values, mean \pm standard error.

Discussion

In the present clinical trial, MBL was investigated at four time points:

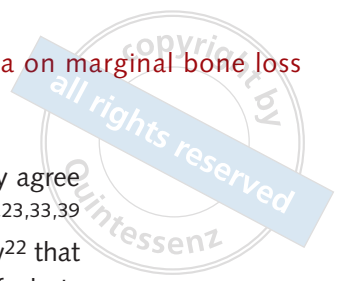
- initial post-surgical period of 4 months from implant placement to prosthetic delivery (T0–T1);
- first 6-month period of prosthetic loading (T1–T2);
- second 6-month period of prosthetic loading (T2–T3);
- third 6-month period of prosthetic loading (T3–T4).

MBL increased across all four time points but at very different rates. The average MBL during the first period (T0–T1) did not differ between the four groups (A1 and A3, thin mucosa; B1 and B3, thick mucosa). Bone loss before loading was limited but noteworthy, as recently described elsewhere²⁷. The greatest amount of bone loss was recorded during the first 6 months of loading (T1–T2), but the 3-mm abutments preserved peri-implant crestal bone more successfully than 1-mm abutments. MBL during the second 6 months of loading (T2–T3) was more limited, with values similar to T0–T1, in close agreement with previous studies^{23,24,33}. The bone loss in all four groups was even lower during T3–T4, with average values less than those recorded during both T0–T1 and T2–T3.

The bone loss rate (calculated as mdMBL) recorded during T0–T1 was very small (slightly greater than 0.01 mm/month) and almost identical in all four groups. Early bone loss may occur during the submerged healing period and may be ascribed to the surgical trauma of implant site preparation^{3,4,7} and subsequent implant insertion^{3,4,8}.

Additionally, stage-two surgery and the two healing abutment disconnections/connections performed between the third and fourth month after implant placement for prosthetic reasons (impression taking and subsequent try-in of the crown) could also have negatively affected early crestal bone remodelling^{4,34}. This limited but nonetheless significant bone loss before implant loading was present in one-third of patients, irrespective of vertical mucosal thickness.

Early bone loss could be considered a predictor of bone alteration over time, as suggested in a recent prospective study²⁷. More specifically, in another article²⁴, MBL > 0.44 mm at 6 months proved to be an indicator of bone loss progression over time. In fact, 97% of these implants showed MBL > 2 mm after 18 months. Therefore, it may be stated that even a limited amount of peri-implant MBL (≈ 0.5 mm) has real and predictive clinical significance. In the present study, the mean MBL at 6 months (T2) was ≈ 0.6 mm (range 0.61 to 0.64 mm) in the 1-mm abutment groups, and ≈ 0.3 mm (range 0.26 to 0.32 mm) in the 3-mm abutment groups. Bone loss during T1–T2 could have been caused primarily by supracrestal tissue height establishment around the implant neck requiring a vertical space greater than 2 mm above the peri-implant crest^{16,20,35,36}. During T2–T3, the low bone loss rate was similar to T0–T1, and this can probably be ascribed to bone's adaptive response to loading. During T3–T4, the bone loss rate dropped to minimum values. Structural peri-implant bone resorption could be considered to have almost concluded and this small amount of bone loss could therefore be ascribed to residual bone remodelling in some patients.



The differences recorded in mdMBL between the two groups of abutments (1 mm and 3 mm) were highly significant during T1–T2, and suggest that only abutments longer than 2 mm could prevent significant MBL. Mucosal thickness had almost no relevance, probably due to its very small or negligible effect on mdMBL when compared with the effect on bone resorption of short abutments during the establishment of supracrestal tissue height.

In order to explain the different bone behaviour in the presence of short and long abutments, some considerations are required. Supracrestal tissue height is the vertical space necessary for the establishment of a mucosal barrier around implants to protect underlying tissue^{15,16}. In recent human histological studies^{37,38}, supracrestal tissue height measured around two-piece implants varied from 3.26 mm to 3.6 mm, which represents the minimum space required for the ideal protective seal. When there is insufficient vertical space for supracrestal tissue height establishment, as is the case in the presence of a 1-mm abutment, marginal bone resorption inevitably occurs irrespective of vertical mucosal thickness²³.

The present outcomes partially agree with previous studies, which demonstrated significantly greater bone loss in thin mucosa (< 2 mm)^{15,29,30,36}. In these latter investigations, however, different prosthetic abutment designs were utilised. Specifically, Berglundh and Lindhe¹⁵, in an animal model, applied healing abutments only, whilst Linkevicius et al^{29,30,36} restored their implants using a conventional prosthetic abutment design, adapting height to the site-specific characteristics of the soft tissue.

Conversely, in the present clinical trial performed to evaluate the simultaneous effect of abutment height and mucosal thickness on peri-implant bone loss, mucosal thickness seemed to play only a marginal role in MBL compared with that played by abutment height. In other words, slightly greater bone loss was recorded in thin mucosa when compared with thick mucosa only when long abutments were used. In groups A1 and B1, the strong negative influence of short abutments on bone remodelling, as occurring irrespective of mucosal thickness, masked the potential effects of vertical soft tissue.

The present authors' outcomes strongly agree with retrospective¹⁶⁻²⁰ and prospective^{21,23,33,39} studies and with a recent systematic review²² that demonstrates the significant influence of abutment height on MBL. Use of a short abutment inevitably leads to a prosthetic restoration with a wide emergence angle, whose correlations with increased marginal bone resorption and occurrence of peri-implantitis have been demonstrated in a recent study⁴⁰.

However, early MBL can be influenced not only by supracrestal tissue height establishment, but also by the inflammatory process elicited by bacteria present in the implant–abutment microgap⁹⁻¹¹. The presence of the microgap at the crestal level could have negatively affected peri-implant bone stability, even if the use of platform-switched internal connections should have reduced this problem. Moreover, it should be noted that this effect was common to all four groups analysed in the present study, thus limiting its significance as potential confounding factor. Furthermore, in the present study a second microgap could be identified at the prosthesis–abutment junction, since an elevated prosthetic abutment with a luted crown was utilised. This prosthetic solution has been demonstrated to give no clinical disadvantage, and a minimal luting gap between the two components is desirable to improve soft tissue adaptation⁴¹. A recent study⁴² showed that marginal and internal adaptation of two-piece luted prostheses after central and/or local manufacturing provides a highly precise fit, comparable with the high-quality standards of CAD/CAM implant-supported prostheses.

A partially unexpected finding of the present study was the slight decrease in vertical mucosal thickness between stage-one and stage-two surgery. This very limited reduction can be explained by soft tissue contraction following surgical trauma. Based on this change, it is possible to speculate that peri-implant mucosal thickness could be unstable over time. Further investigations with longer follow-ups and more measurements over time are required.

The present study and several previous investigations^{21,23,29,30,32,36,39} do not consider



medium-thickness mucosa as a separate group, as recently proposed in the literature⁴³. Therefore, further studies should investigate not only the effect of thin and thick mucosa, but also the eventual effect of medium-thickness mucosa on crestal bone loss.

A limitation of the present study is the fact that assessment of MBL only referred to the mesial and distal aspects of each implant, thus excluding mid-facial and mid-lingual measurements. Therefore, the present outcomes are not representative of 3D bone remodelling, but analyse only its “bi-dimensional” mesial and distal aspect.

Furthermore, the influence of other confounding factors such as smoking, oral hygiene and periodontal disease was not investigated in this present 18-month study and may affect longer-term peri-implant bone loss, as reported elsewhere⁴⁴.

Conclusions

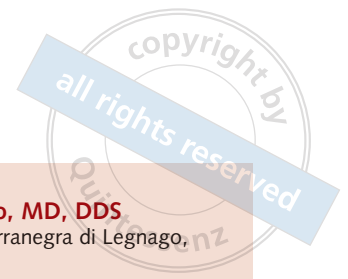The pattern of MBL over time revealed that the greatest amount of peri-implant bone resorption occurs in the first 6 months after prosthetic loading. After this time, peri-implant bone levels tend to stabilise, and no further significant modifications were recorded up to 18 months of prosthetic loading. The results of the present investigation showed that platform-switched implants with internal connection placed equicrestally and restored with short abutments (1 mm) presented greater MBL than identical implants with long abutments (3 mm), and that peri-implant mucosal thickness plays only a very limited role in MBL compared with that played by abutment height.

The outcomes of this randomised clinical trial require confirmation by further studies conducted in different areas of the mouth and with a larger sample size.

References

- Adell R, Lekholm U, Rockler B, Brånemark PI. A 15-year study of osseointegrated implants in the treatment of the edentulous jaw. *Int J Oral Surg* 1981;10:387–416.
- Albrektsson T, Zarb G, Worthington P, Eriksson AR. The long-term efficacy of currently used dental implants: A review and proposed criteria of success. *Int J Oral Maxillofac Implants* 1986;1:11–25.
- Oh TJ, Yoon J, Misch CE, Wang HL. The causes of early implant bone loss: Myth or science? *J Periodontol* 2002;73:322–333.
- Tatarakis N, Bashutski J, Wang HL, Oh TJ. Early implant bone loss: Preventable or inevitable? *Implant Dent* 2012; 21:379–386.
- Albrektsson T, Chrcanovic B, Östman PO, Sennerby L. Initial and long-term crestal bone responses to modern dental implants. *Periodontol* 2000 2017;73:41–50.
- Avila-Ortiz G, Gonzalez-Martin O, Couso-Queiruga E, Wang HL. The peri-implant phenotype. *J Periodontol* 2020;91:283–288.
- Barone A, Alfonsi F, Derchi G, et al. The effect of insertion torque on the clinical outcome of single implants: A randomized clinical trial. *Clin Implant Dent Relat Res* 2016; 18:588–600.
- Baldi D, Lombardi T, Colombo J, et al. Correlation between insertion torque and implant stability quotient in tapered implants with knife-edge thread design. *Biomed Res Int* 2018;2018:7201093.
- Broggini N, McManus LM, Hermann JS, et al. Peri-implant inflammation defined by the implant-abutment interface. *J Dent Res* 2006;85:473–478.
- Piattelli A, Vrespa G, Petrone G, Iezzi G, Annibali S, Scarano A. Role of the microgap between implant and abutment: A retrospective histologic evaluation in monkeys. *J Periodontol* 2003;74:346–352.
- Baffone GM, Botticelli D, Canullo L, Scala A, Beolchini M, Lang NP. Effect of mismatching abutments on implants with wider platforms—an experimental study in dogs. *Clin Oral Implants Res* 2012;23:334–339.
- Norton MR. Marginal bone levels at single tooth implants with a conical fixture design. The influence of surface macro- and microstructure. *Clin Oral Implants Res* 1998;9:91–99.
- Shin YK, Han CH, Heo SJ, Kim S, Chun HJ. Radiographic evaluation of marginal bone level around implants with different neck designs after 1 year. *Int J Oral Maxillofac Implants* 2006;21:789–794.
- Ericsson I, Persson LG, Berglundh T, Marinello CP, Lindhe J, Klinge B. Different types of inflammatory reactions in peri-implant soft tissues. *J Clin Periodontol* 1995;22: 255–261.
- Berglundh T, Lindhe J. Dimension of the periimplant mucosa. Biological width revisited. *J Clin Periodontol* 1996;23, 971–973.
- Galindo-Moreno P, León-Cano A, Ortega-Oller I, et al. Prosthetic abutment height is a key factor in peri-implant marginal bone loss. *J Dent Res* 2014;93(7 suppl):805–855.
- Galindo-Moreno P, León-Cano A, Monje A, Ortega-Oller I, O'Valle F, Catena A. Abutment height influences the effect of platform switching on peri-implant marginal bone loss. *Clin Oral Implants Res* 2016;27:167–173.
- Spinato S, Bernardello F, Sassatelli P, Zaffe D. Hybrid implants in healthy and periodontally compromised patients: A preliminary clinical and radiographic study. *Int J Periodontics Restorative Dent* 2017;37:195–202.

19. Spinato S, Bernardello F, Sassatelli P, Zaffe D. Hybrid and fully-etched surface implants in periodontally healthy patients: A comparative retrospective study on marginal bone loss. *Clin Implant Dent Relat Res* 2017;19:663–670.
20. Spinato S, Galindo-Moreno P, Bernardello F, Zaffe D. Minimum abutment height to eliminate bone loss: Influence of implant neck design and platform switching. *Int J Oral Maxillofac Implants* 2018;33:405–411.
21. Blanco J, Pico A, Caneiro L, Nóvoa L, Batalla P, Martín-Lancharro P. Effect of abutment height on interproximal implant bone level in the early healing: A randomized clinical trial. *Clin Oral Implants Res* 2018;29:108–117.
22. Chen Z, Lin CY, Li J, Wang HL, Yu H. Influence of abutment height on peri-implant marginal bone loss: A systematic review and meta-analysis. *J Prosthet Dent* 2019;122:14–21.e2.
23. Spinato S, Stacchi C, Lombardi T, Bernardello F, Messina M, Zaffe D. Biological width establishment around dental implants is influenced by abutment height irrespective of vertical mucosal thickness: A cluster randomized controlled trial. *Clin Oral Implants Res* 2019;30:649–659.
24. Galindo-Moreno P, León-Cano A, Ortega-Oller I, Monje A, O'Valle F, Catena A. Marginal bone loss as success criterion in implant dentistry: Beyond 2 mm. *Clin Oral Implants Res* 2015;26:e28–e34.
25. Linkevicius T, Puisys A, Svediene O, Linkevicius R, Linkeviciene L. Radiological comparison of laser-microtextured and platform-switched implants in thin mucosal biotype. *Clin Oral Implants Res* 2015;26:599–605.
26. Hsu YT, Oh TJ, Rudek I, Wang HL. The effect of initial phase bone remodeling upon implant wound healing. *Int J Periodontics Restorative Dent* 2016;36:737–743.
27. Borges T, Leitão B, Pereira M, Carvalho A, Galindo-Moreno P. Influence of the abutment height and connection timing in early peri-implant marginal bone changes: A prospective randomized clinical trial. *Clin Oral Implants Res* 2018;29:907–914.
28. World Medical Association. World Medical Association declaration of Helsinki: Ethical principles for medical research involving human subjects. *JAMA* 2013;310:2191–2194.
29. Linkevicius T, Apse P, Grybauskas S, Puisys A. Influence of thin mucosal tissues on crestal bone stability around implants with platform switching: A 1-year pilot study. *J Oral Maxillofac Surg* 2010;68:2272–2277.
30. Linkevicius T, Puisys A, Steigmann M, Vindasiute E, Linkeviciene L. Influence of vertical soft tissue thickness on crestal bone changes around implants with platform switching: A comparative clinical study. *Clin Implant Dent Relat Res* 2015;17:1228–1236.
31. Gomez-Roman G, Launer S. Peri-implant bone changes in immediate and non-immediate root-analog stepped implants-A matched comparative prospective study up to 10 years. *Int J Implant Dent* 2016;2:15.
32. Glantz, SA. *Primer of Biostatistics*, ed 6. New York: Mc-Graw Hill, 2007.
33. Lombardi T, Berton F, Salgarello S, et al. Factors influencing early marginal bone loss around dental implants positioned subcrestally: A multicenter prospective clinical study. *J Clin Med* 2019;8:1168.
34. Koutouzis T, Gholami F, Reynolds J, Lundgren T, Kotsakis GA. Abutment disconnection/reconnection affects peri-implant marginal bone levels: A meta-analysis. *Int J Oral Maxillofac Implants* 2017;32:575–581.
35. Hermann JS, Schoolfield JD, Nummikoski PV, Buser D, Schenk RK, Cochran DL. Crestal bone changes around titanium implants: A methodologic study comparing linear radiographic with histometric measurements. *Int J Oral Maxillofac Implants* 2001;16:475–485.
36. Linkevicius T, Apse P, Grybauskas S, Puisys A. The influence of soft tissue thickness on crestal bone changes around implants: A 1-year prospective controlled clinical trial. *Int J Oral Maxillofac Implants* 2009 24:712–719.
37. Judgar R, Giro G, Zenobio E, et al. Biological width around one- and two-piece implants retrieved from human jaws. *Biomed Res Int* 2014;8:50120.
38. Tomasi C, Tessarolo F, Caola I, Wennström J, Nollo G, Berglundh T. Morphogenesis of peri-implant mucosa revisited: An experimental study in humans. *Clin Oral Implants Res* 2014;25:997–1003.
39. Pico A, Martín-Lancharro P, Caneiro L, Nóvoa L, Batalla P, Blanco J. Influence of abutment height and implant depth position on interproximal peri-implant bone in sites with thin mucosa: A 1-year randomized clinical trial. *Clin Oral Implants Res* 2019;30:595–602.
40. Katafuchi M, Weinstein BF, Leroux BG, Chen YW, Daubert DM. Restoration contour is a risk indicator for peri-implantitis: A cross-sectional radiographic analysis. *J Clin Periodontol* 2018;45:225–232.
41. Mehl C, Gassling V, Schultz-Langerhans S, et al. Influence of four different abutment materials and the adhesive joint of two-piece abutments on cervical implant bone and soft tissue. *Int J Oral Maxillofac Implants* 2016;31:1264–1272.
42. Gehrke P, Sing T, Fischer C, Spintzyk S, Geis-Gerstorf J. Marginal and internal adaptation of hybrid abutment assemblies after central and local manufacturing, respectively. *Int J Oral Maxillofac Implants* 2018;33:808–814.
43. Linkevicius T, Linkevicius R, Alkimavicius J, Linkeviciene L, Andrijauskas P, Puisys A. Influence of titanium base, lithium disilicate restoration and vertical soft tissue thickness on bone stability around triangular-shaped implants: A prospective clinical trial. *Clin Oral Implants Res* 2018;29:716–724.
44. Vervaeke S, Collaert B, Cosyn J, De Bruyn H. A 9-year prospective case series using multivariate analyses to identify predictors of early and late peri-implant bone loss. *Clin Implant Dent Relat Res* 2016;18:30–39.



Sergio Spinato

Sergio Spinato, DDS

Private Practice, Sassuolo, Modena, Italy

Claudio Stacchi, DDS, MSc

Adjunct Professor, Department of Medical, Surgical and Health Sciences, University of Trieste, Trieste, Italy

Teresa Lombardi, DDS

Adjunct Professor, Department of Health Sciences, University Magna Graecia, Catanzaro, Italy

Fabio Bernardello, MD, DDS

Private Practice, Terranegra di Legnago, Verona, Italy

Marcello Messina, DDS

Private Practice, Trieste, Italy

Sergio Dovigo, MD, DDS

Private Practice, Noventa Vicentina, Vicenza, Italy

Davide Zaffe, MBiolSc

Professor, Department of Biomedical, Metabolic and Neural Sciences, University of Modena and Reggio Emilia, Modena, Italy

Correspondence to:

Professor Davide Zaffe, Department of Biomedical, Metabolic and Neural Sciences, Human Morphology Section, University of Modena and Reggio Emilia, Via del Pozzo 71, Policlinico, 41124 Modena, Italy. Email: davide.zaffe@unimore.it